

A Camille

1	APPARENT MODE <b>ACCIDENT</b>	CASE NO 2010-01701
	SPECIAL CIRCUMSTANCES Celebrity, Media Interest	CRYPT SC

125/1965

LAST, FIRST MIDDLE <b>HAIM, COREY IAN</b>	AKA	#
--	-----	---

ADDRESS	CITY <b>LOS ANGELES</b>	STATE <b>CA</b>	ZIP
---------	----------------------------	--------------------	-----

SEX MALE	RACE APPEARS CAUCASIAN	DOB 12/23/1971	AGE 38	HGT 67 in.	WGT 200 lbs.	EYES BLUE	HAIR BROWN	TEETH ALL NATURAL TEETH	FACIAL HAIR UNSHAVEN	ID VIEW Yes	CONDITION FAIR
-------------	---------------------------	-------------------	-----------	---------------	-----------------	--------------	---------------	----------------------------	-------------------------	----------------	-------------------

MARK TYPE	MARK LOCATION	MARK DESCRIPTION
TATTOO	RIGHT SHOULDE	"THOU SHALL NOT FALL", "LB 12"
TATTOO	RIGHT SHOULDE	BAT
TATTOO	LEFT ARM	"THE HAIMSTER"
TATTOO	CHEST	CLOWN FACE WITH FLAMES

NOTIFIED BY	DATE	TIME
	3/10/2010	02:15

DL ID A3277981	STATE CA	PENDING BY
-------------------	-------------	------------

ID METHOD  
FINGERPRINTS FROM LASD

LA #	MAIN #	CH #	FBI #	MILITARY #	POB
------	--------	------	-------	------------	-----

IDENTIFIED BY NAME (PRINT) PRINTS LFIS, DOJ, FBI, ICE	RELATIONSHIP	PHONE	DATE	TIME
			3/10/2010	06:24

PLACE OF DEATH / PLACE FOUND HOSPITAL PROVIDENCE ST. JOSEPH MED CNTR	ADDRESS OR LOCATION 501 S. BUENA VISTA STRRET	CITY BURBANK	ZIP 91505
--	--	-----------------	--------------

PLACE OF INJURY UNKNOWN	AT WORK No	DATE	TIME	LOCATION OR ADDRESS	ZIP
----------------------------	---------------	------	------	---------------------	-----

DOD 3/10/2010	TIME 02:15	FOUND OR PRONOUNCED BY DR. PAMELA BIREN
------------------	---------------	--

OTHER AGENCY INV. OFFICER LAPD NORTH HOLLYWOOD	PHONE	REPORT NO.	NOTIFIED BY	NO
---	-------	------------	-------------	----

TRANSPORTED BY JULIE M. BISHOP	TO LOS ANGELES FSC	DATE	TIME
		3/10/2010	06:05

FINGERPRINTS? Yes	CLOTHING Yes	PA RPT No	MORTUARY
MED. EV. Yes	INVEST. PHOTO # 13	SEAL TYPE	HOSP RPT Yes
PHYS. EV. No	EVIDENCE LOG Yes	PROPERTY? No	HOSP CHART Yes
SUICIDE NOTE No	QSR NO	RCPT. NO.	PF NO. N000044826

SYNOPSIS  
 ACCORDING TO THE REPORTED INFORMATION, ON 3/10/2010 AT APPROXIMATELY 0030 HOURS, THE DECEDENT APPEARED DISORIENTED THEN COLLAPSED ONTO HIS KNEES. HIS MOTHER HELPED HIM BACK INTO BED. HIS BODY BEGAN TO SHAKE IN ALL DIRECTIONS AND HIS EYES ROLLED BACK. HIS MOTHER CALLED 911. LAFD RA 60 TRANSPORTED THE DECEDENT TO PROVIDENCE SAINT JOSEPH MEDICAL CENTER WHERE DEATH WAS PRONOUNCED IN THE EMERGENCY ROOM ON 3/10/2010 AT 0215 HOURS. ON 3/9/2010 HAD A FEVER AND COUGH. ON 3/5/2010 PRESCRIBED DIAZEPAM, CARISOPRODOL, HYDROCODONE-APAP, HALOPERIDOL, AND ZYPREXA. HISTORY OF MULTIPLE PRESCRIPTION MEDICATION ABUSE. DECEDENT ADMITTED IN PAST INTERVIEWS TO USING COCAINE (UNKNOWN WHEN LAST USED). HISTORY OF HEART MURMUR AND POSSIBLY HYPERTENSION. NO OBVIOUS SIGNS OF TRAUMA WERE FOUND. FOUL PLAY IS NOT SUSPECTED.

KIMBERLEY ARNOLD 498313 <i>Kimberley Arnold</i>	INVESTIGATOR	DATE 3/10/2010	TIME 14:08	REVIEWED BY <i>[Signature]</i>	DATE 3/10/10	TIME
--	--------------	-------------------	---------------	-----------------------------------	-----------------	------

FORM #3 NARRATIVE TO FOLLOW?



County of Los Angeles, Department of Coroner  
Investigator's Narrative



Case Number: 2010-01701

Decedent: HAIM, COREY IAN

**Information Sources:**

Los Angeles Fire Department Emergency Medical Service Report #CD 072378  
Providence Saint Joseph Medical Center, (818) 847-4043, Medical record #N000044826  
LAPD N. Hollywood Officers Orellana and Castaneda, (818) 623-4016, Inc#100310000443  
LAPD N. Hollywood Officers Escobedo and Espinosa, (818) 623-4016, Inc#100310000443

**Investigation:**

On 3/10/2010 at 0434 hours Marcus Duson from Providence Saint Joseph Medical Center reported this accidental (suspected prescription medication overdose) death to Lt. Larry Dietz of the Forensic Science Center. Lt. Larry Dietz assigned me this field call at 0448 hours. I arrived at Providence Saint Joseph Medical Center at 0520 hours. I completed my investigation there at 0555 hours and arrived at the decedent's residence at 0605 hours. I completed my investigation there at 0640 hours and arrived at LAPD North Hollywood station at 0655 hours. I completed my investigation there at 0750 hours and returned to the Forensic Science Center. Supervising Forensic Attendant Julie Bishop transported the decedent to the Forensic Science Center.

**Location:**

Injury: unknown

Death: Providence Saint Joseph Medical Center – 501 S. Buena Vista St., Burbank, CA 91505

**Informant/Witness Statements:**

According to the EMS report, on 3/10/2010 at 0054 hours, LAFD RA 60 was dispatched to 3640 Barham Boulevard, arriving at 0105 hours. Patient in bed supine, multiple "drug use per family". Unknown down time. Patient "in bed all day". At 0104 hours blood pressure 0, pulse 0, respirations 0, in asystole. Fixed/dilated pupils. Blood glucose 162. No trauma, no vomitus. Endotracheal tube placed. Positive chest rise, pulses with CPR. Given normal saline, narcan, epinephrine x4, and atropine x2, bicarb x1. Defibrillated x1. Transported to the hospital at 0125 hours. Arrived at the hospital at 0134 hours. Restoration of pulses at 0138 hours. Medication history of Haldol, Seroquel.

According to the medical records provided by Providence Saint Joseph Medical Center, the decedent presented to the emergency room via LAFD RA 60 on 3/10/2010 at 0134 hours with CPR in progress. No injuries noted. Cardiac rhythm went from agonal to asystolic. CPR stopped at 0158 hours due to return of pulse 160, blood pressure 144/58. Faded back to asystole. CPR continued, however, the decedent remained asystolic. Dr. Pamela Biren pronounced death in the emergency room on 3/10/2010 at 0215 hours. Cut clothing to expose femoral artery. History: recovering drug addict, fracture right tibia, arrhythmia, hypertension. No known allergies. On 2/28/2010 prescribed Carisoprodol and Diazepam by emergency room doctor.

According to the LAPD report, on 3/10/2010 at approximately 0350 hours Officers Orellana and Castaneda received a radio call of a death investigation at St. Josephs Hospital. Upon arrival to the hospital they met RA 60. RA 60 explained that upon their arrival at the subject's residence, Corey Haim was given CPR by his mother in an attempt to revive Corey Haim with negative results. RA 60 observed an empty prescription bottle of Haldol. LAFD Engine 76 arrived approximately 5 minutes prior to RA 60. RA 60 transported Corey Haim to St. Josephs Hospital and continued administering CPR. Upon arrival at the hospital Corey Haim was pronounced dead at 0215 hours by Doctor Pamela Biren. Probable cause of death was from cardiopulmonary arrest.

Ka





County of Los Angeles, Department of Coroner  
Investigator's Narrative



Case Number: 2010-01701

Decedent: HAIM, COREY IAN

According to the LAPD report, on 3/9/2010 (date incorrect) at 0405 hours Officers Escobedo and Espinosa responded with Officers Castaneda and Orellana to Saint Joseph's Hospital for a death investigation. Officers Escobedo and Espinosa conducted a follow-up to the residence of Corey Haim. \_\_\_\_\_ were at the residence.

\_\_\_\_\_ advised that she also resides at the residence. \_\_\_\_\_ stated that her son Corey Haim had been sick in the recent past but she believed he had been getting better.

\_\_\_\_\_ stated that on 3/8/2010 at approximately 1630 hours her son told her that he wasn't feeling well and had a fever. She stated her son went to bed and coughed all throughout the night. Her son stayed in bed all day on 3/9/2010 and she made him some tea and vegetable soup. She gave him Robitussin and Advil every 4 hours because he complained of a severe headache, and she gave him Tylenol for his fever. He had a suppository because he was feeling nauseated and a Zophren. His breathing was short and fast and she told him not to lie on his back. Later in the evening he asked her to lay down with him because he wasn't feeling well. She held his hand and fell asleep. She woke up when she heard him get up and walk to the kitchen. She then heard him return to the bedroom where he fell down onto his knees. She helped him up and put him back in bed. She asked him what was wrong and he did not respond. She called 911. He stopped breathing and was unresponsive. She was advised by the 911 operator to conduct CPR until responding units could arrive. She performed CPR until the paramedics arrived. Sgt. McNeil arrived on scene and advised. There were several bottles of prescription medication in the name of Corey Haim in his bedroom in the drawer next to his bed. Zyprexa (4 left in bottle), Diazepam (1 left in bottle), Haloperidol (empty), and Carisoprodol (empty). All prescribed 3/5/2010. Found in the mother's purse, prescribed to Corey Haim, was Hydrocodone APAP (also prescribed 3/5/2010 and empty). All medications filled at CVS Pharmacy and prescribed by Dr. Rod Amiri. His mother stated that she took the Hydrocodone bottle with her to St. Joseph's when her son was transported. That was the only bottle that was completely empty. When she returned from the hospital she emptied the other bottles into the toilet because she didn't want anyone else to get hold of the medication and she didn't know the police would be responding to her residence.

I spoke with \_\_\_\_\_ at her residence. She told me that the decedent stayed in bed all day on 3/9/2010 with a fever (101 degrees to 99 degrees) and cough. He stayed in the bedroom most of the day and spent some time on the couch. He complained of a headache from the coughing. She gave him 2 Advil every 4 hours. He vomited and felt nauseous. She gave him 1 Zofran tablet, 1 tablespoon of Robitussin, and a suppository. He complained of a lower backache most of the day. He had been doing well lately. He was not getting "high" (prescription medication high) because he had a fever. At approximately 0030 hours he got out of bed and it appeared he was on his way to the bathroom or the kitchen. He appeared to be disoriented. He fell onto his knees between the television and the bed. She asked him what was wrong. He said he did not know. She helped him onto the bed. His body began to shake in all directions and his eyes rolled back. She called 911 and was instructed to place him on the floor and begin CPR. For a few hours before he collapsed he was not breathing well, it was abnormally fast. The decedent usually took 7 Tylenol PM's every night to help him sleep. He did not take any the night of 3/9/2010. He was in and out of rehabilitation for prescription drug use. No history of alcohol or illegal/illicit drug use except marijuana use – possibly last used 2 days ago. Cigarette smoker. Medical history included a heart murmur diagnosed many years ago, possibly had high blood pressure. No heart attack or stroke history in the family. She flushed 7 Carisoprodol down the toilet after he died. Dr. Rod Amiri gave him 1/2 the amount he usually did, he was trying to take him down, reduce the amount of medication he was prescribing to him. The decedent was not depressed or suicidal. No known history of suicidal ideations or attempts. No suicide note found.

Ka



County of Los Angeles, Department of Coroner  
Investigator's Narrative



Case Number: 2010-01701

Decedent: HAIM, COREY IAN

**Scene Description:**

The hospital scene appears to be a typical room within the emergency room. The decedent is located on a gurney in the middle of the room. There is medical equipment throughout the room. The residential scene is a 2 bedroom apartment located in a sprawling complex. The residence is well-furnished and tidy.

**Evidence:**

From the residence I collected prescription medications diazepam (empty), carisoprodol (empty), hydrocodone-apap (empty), haloperidol (empty), Zyprexa (4 of 7 remained) – all of these were prescribed on 3/5/2010. In the bedroom trashcan I found over the counter medication Tylenol PM (3 of 20 remained), chloraseptic lozenges, phenol oral anesthetic spray, and vaporub. Prescription medication Levaquin (1 in a blister pack) and Bystolic (1 of 7 remained) were found in the bedroom trashcan without prescription information. I booked all the Forensic Science Center.

**Body Examination:**

The decedent is supine on a hospital gurney and is covered up to his neck with a hospital sheet. An endotracheal tube with mouthblock, right antecubital IV, and left hand dorsum IV are in place. EKG patch and defibrillator pad residue noted on the chest and abdomen. The decedent is wearing a pair of cut dark gray shorts. An unknown light green substance is on his tongue and lips. A scab noted to the inner right index finger. Multiple tattoos were noted: "Thou Shall Not Fail", "LB 12", and a bat on the right shoulder, a set of paws and unknown writing on the right forearm, a bat on the inner left wrist, clown face with flames on the upper left chest, "The Haimster" and design on the upper left arm, design and "2 2 2" on the outer right leg, unknown design on the upper left back. No scars or obvious signs of trauma were found. Rigor mortis was rated as 0 throughout the decedent. Lividity was consistent with the supine position (as seen at the hospital) and blanched with finger pressure.

**Identification:**

LFIS fingerprints identified the decedent as Corey Haim on 3/10/2010 at 0624 hours.

**Next of Kin Notification:**


I spoke with \_\_\_\_\_ at her residence and verified that she was notified of the death.

**Tissue Donation:**

Unknown.

**Autopsy Notification:**

None requested.



KIMBERLEY ARNOLD 498313



SUPERVISOR

3/10/2010

Date of Report



**3A**

**FORM:**

CAPSULE C  
 LIQUID L  
 POWDER P  
 SUPPOSITORY S  
 TABLET T

**NOTE: IF MEDICATION IS NOT IDENTIFIED, MAKE NOTE OF TABLET COLOR, SHAPE, MARKINGS AND NUMBER.**

2010-0701  
 HAIM, COREY  
 ACC  
 3/10/2010

PAGE 1 OF 2

Rx Number	Date of Issue	Drug Name / Description	Number Issued	Number Remaining	Form	Dosage	Rx Directions	Physician	Pharmacy Phone / Comments
C891071	3/5/2010	DAZEPA M	21	0	T	10mg	1 TAB 3 X'S A DAY.	ROO AMIRI	
891069	3/5/2010	ZYPREXA	7	4	T	7.5mg	1 TAB AT BEDTIME.	ROO AMIRI	
891073	3/5/2010	CALISOPRODOL	57	0/7	T	350mg	1 TAB 3 X'S A DAY.	ROO AMIRI	7 REMAINED, THEN MOTHER FLUSHED THEM DOWN TOILET.
C891072	3/5/2010	HYDROCODONE-APAP	42	0	T	7.5-750mg	1-2 TABS EVERY 6 HOURS AS NEEDED	ROO AMIRI	
143693	3/5/2010	HALOPERIDOL	7	0	T	10mg	1 TAB A DAY AS NEEDED.	ROO AMIRI	
NO RX INFO		LEVAQUIN	UNK	1	T	500mg			
NO RX INFO PROFESSIONAL SAMPLE		BYSTOLIC	7	1	T	5mg			

**PARAPHERNALIA DESCRIPTION:**

K. Arnold  
 INVESTIGATOR  
3/10/2010  
 DATE

**3A**

**FORM:**

CAPSULE C  
 LIQUID L  
 POWDER P  
 SUPPOSITORY S  
 TABLET T

NOTE: IF MEDICATION IS NOT IDENTIFIED,  
 MAKE NOTE OF TABLET COLOR, SHAPE,  
 MARKINGS AND NUMBER.

200-0701  
 HAIM, COLEY  
 ACC  
 3/10/2010

PAGE 2 OF 2

Rx Number	Date of Issue	Drug Name / Description	Number Issued	Number Remaining	Form	Dosage	Rx Directions	Physician	Pharmacy Phone / Comments
OVER THE COUNTER		TYLENOL PM	20	3	GEL-CAPS	500MG			
OVER THE COUNTER		CHLORASEPTIC LOZENGES	UNK	3	LOZENGES	UNK			
OVER THE COUNTER		PHENOL/ORAL ANESTHETIC	1	1	LIQUID	UNK			
OVER THE COUNTER		VAPORUB							

PARAPHERNALIA DESCRIPTION:

K. Arnold  
 INVESTIGATOR  
3/10/2010  
 DATE




**12****AUTOPSY REPORT**

No.

2010-01701

HAIM, COREY

I performed an autopsy on the body of   
at \_\_\_\_\_  
the DEPARTMENT OF CORONER

Los Angeles, California

on MARCH 11, 2010 @ 0900 HOURS  
(Date) (Time)

From the anatomic findings and pertinent history I ascribe the death to:

(A) DIFFUSE ALVEOLAR DAMAGE

DUE TO, OR AS A CONSEQUENCE OF

(B) COMMUNITY ACQUIRED PNEUMONIA

DUE TO, OR AS A CONSEQUENCE OF

(C)

DUE TO, OR AS A CONSEQUENCE OF

(D)

OTHER CONDITIONS CONTRIBUTING BUT NOT RELATED TO THE IMMEDIATE CAUSE OF DEATH:

HYPERTROPHIC CARDIOMYOPATHY WITH CORONARY ARTERIOSCLEROSIS**Anatomical Summary:**

- I. Cardiomegaly.
- A. Enlarged heart 530 grams.
  - B. Adhesion of left ventricle to pericardial sac.
  - C. Biventricular hypertrophy.
  - D. Thickening of mitral and tricuspid valves.
  - E. Atherosclerotic vascular disease.
    1. 50% narrowing grossly of proximal anterior descending branch of left coronary artery.
    2. Up to 75% narrowing by microscopy.
- II. Pulmonary congestion.
- A. Heavy congested edematous.
  - B. No masses or lesions.
- III. Hepatomegaly.
- A. Enlarged liver 2940 grams.
- IV. Abrasion to right elbow.
- V. See Toxicology Report.

**12****AUTOPSY REPORT**

No.

2010-01701

HAIM, COREY

Page 2

## SUMMARY OF EVENTS:

The decedent is a 38-year-old Caucasian male who reportedly collapsed at home at or around 1254 in the morning on 3/10/10. Ambulance initiated CPR and transported Mr. Haim to Providence St. Joseph Medical Center where despite medical intervention he was pronounced dead on 3/10/10 at 0215 hours.

## EXTERNAL EXAMINATION:

The body is identified by toe tags and is that of an unembalmed, refrigerated adult male Caucasian who appears about the reported age of 38 years. The body weighs 200 pounds, measures 67 inches, and appears well built, muscular and well nourished. A 1-1/2 x 1/4 inch superficial red abrasion is noted to the right elbow. No other injuries, scars or bruises are noted. Multiple tattoos are present consisting of the following: a multicolored face mask is noted to the left chest; a bat is noted to the left ventral wrist; a blue and black band is noted to the left upper arm with a circular design and the words "The Haimster" noted. There is a tattoo of a panther and numerous bats to the left upper superior arm. There is a tattoo of a bat with the words "Thou shalt not fall" on the right upper arm; on the right dorsal forearm is a design with multiple letters which I cannot make out. On the right ventral forearm are tattoos of paws. On the left upper back is a green and black tattoo. On the right lower leg is a black and red design tattoo. Rigor is present. Livor mortis is fixed and dependent.

The head is normocephalic and covered by brown hair. There is no balding and the hair can be described as short and wavy. Stubble is noted along the distribution of a mustache and beard. Examination of the eyes reveals irides that appear to be blue in color and sclerae that are white. There are no petechial hemorrhages of the conjunctivae of the lids or the sclerae. The oronasal passages are unobstructed. Upper and lower teeth are present. The neck is unremarkable. There is no chest deformity. There is no increased anterior-posterior diameter. The abdomen is slightly distended. The genitalia are those of an adult male. The penis appears circumcised. The external genitalia are without trauma or lesions. The extremities show no edema, joint deformity, abnormal mobility, or needle tracks.



**12****AUTOPSY REPORT**

No.

2010-01701

HAIM, COREY

Page 3

## EVIDENCE OF THERAPEUTIC INTERVENTION:

The following are present and are in proper position: endotracheal tube; intravenous lines to the dorsum of the left hand and right antecubital fossa. There has not been postmortem intervention for organ procurement.

## CLOTHING:

The body was not clothed and I did not see the clothing.

## INITIAL INCISION:

The body cavities are entered through the standard coronal incision and the standard Y-shaped incision. No foreign material is present in the mouth, upper airway and trachea.

## NECK:

The neck organs are removed en bloc with the tongue. No lesions are present nor is trauma of the gingiva, lips or oral mucosa demonstrated. There is no edema of the larynx. Both hyoid bone and larynx are intact and without fractures. No hemorrhage is present in the adjacent throat organs, investing fascia, strap muscles, thyroid or visceral fascia. There are no prevertebral fascial hemorrhages. The tongue when sectioned shows no trauma.

## CHEST/ABDOMINAL CAVITY:

Both pleural cavities contain minimal serous fluid. The lungs are voluminous. Soft tissues of the thoracic and abdominal walls are well-preserved. The organs of the abdominal cavity have a normal arrangement and none are absent. There is no fluid collection. The peritoneal cavity is without evidence of peritonitis. There are no adhesions.

**12****AUTOPSY REPORT**

No.

2010-01701

HAIM, COREY

Page 4SYSTEMIC AND ORGAN REVIEW

The following observations are limited to findings other than injuries, if described above.

**MUSCULOSKELETAL SYSTEM:**

No abnormalities of the bony framework or muscles are present.

**CARDIOVASCULAR SYSTEM:**

The aorta is elastic and of even caliber throughout, with vessels distributed normally from it. Both abdominal and thoracic aorta have minimal lipid streaking. There is no dilation of the lower abdominal segment. No aneurysm is present. The major branches of the aorta show no abnormality. Within the pericardial sac there is a minimal amount of serous fluid. An adhesion is noted between the distal left ventricle and to the pericardial sac. The heart weighs 530 grams. It has biventricular hypertrophy. The right ventricle is 0.7 cm thick and the left ventricle is 2 cm thick. The chambers are normally developed and are without mural thrombosis. Both mitral and tricuspid valves show thickening of the leading edge of the cusps. Circumference of valve rings are: Tricuspid valve 12.3 cm, pulmonic valve 6.7 cm, mitral valve 9.5 cm and aortic valve 6.1 cm. There is slight thickening with yellow to white discoloration of the outflow tract of the left ventricle endocardium. There are no lesions of the myocardium. There is slight thickening of the apices of the papillary musculature of the mitral valve. There are no defects of the septum. The great vessels enter and leave in a normal fashion. The coronary ostia are widely patent. There is a balanced pattern of coronary artery distribution. There is segmental atherosclerosis with up to 50% narrowing of the proximal anterior descending branch of the left coronary artery. No focal endocardial, valvular or myocardial lesions are seen. The blood within the heart and large blood vessels is liquid.

**RESPIRATORY SYSTEM:**

An extremely large amount of edema is found in the lower bronchial passages. The mucosa is severely injected throughout. The lungs are subcrepitant and there is dependent congestion.



**12****AUTOPSY REPORT**

No.

2010-01701

HAIM, COREY

Page 5

The left lung weighs 1230 grams, and the right lung weighs 1370 grams. The visceral pleura are smooth and intact. The parenchyma is extremely congested and edematous, however no consolidation is noted. The pulmonary vasculature is without thromboembolism.

**GASTROINTESTINAL SYSTEM:**

The esophagus is intact throughout. The stomach is not distended by gas. It does contain fluid. It contains approximately 450 cc of green fluid. The mucosa is unremarkable. No tablets or capsules are identified in the stomach, small intestine or colon. The appendix is present. The pancreas occupies a normal position. There is no trauma. The parenchyma is lobular and firm. The pancreatic ducts are not ectatic and there is no parenchymal calcification.

**HEPATOBIILIARY SYSTEM:**

The liver weighs 2940 grams, is enlarged and is red-brown. The capsule is intact and the consistency of the parenchyma is firm. The cut surface is smooth. There is chronic passive congestion. The gallbladder is present. The wall is thin and pliable. It contains 10 cc bile and no calculi. There is no obstruction or dilation of the extrahepatic ducts. The periportal lymph nodes are not enlarged.

**URINARY SYSTEM:**

The left kidney weighs 220 grams, the right kidney weighs 190 grams. The kidneys are normally situated and the capsule strip easily revealing a surface that is smooth and congested. The corticomedullary demarcation is preserved. The pyramids are not remarkable. The peripelvic fat is not increased. The ureters are without dilation or obstruction and pursue their normal course. The urinary bladder is unremarkable. It contains 50 cc of amber colored urine.

**GENITAL SYSTEM (MALE):**

The prostate is without enlargement or nodularity. Both testes are in the scrotum, are unremarkable and without trauma.

**12****AUTOPSY REPORT**

No.

2010-01701

HAIM, COREY

Page 6

## HEMOLYMPHATIC SYSTEM:

The spleen weighs 280 grams and is of average size. The capsule is intact. The parenchyma is dark red and mushy. There is no increase follicular pattern. Lymph nodes throughout the body are small and inconspicuous. The bone is not remarkable. The bone marrow of the rib is red and moist.

## ENDOCRINE SYSTEM:

The thyroid is unremarkable. The parathyroid glands are not identified. The adrenals are intact without necrosis or hemorrhage. The thymus is unremarkable. The pituitary gland is unremarkable.

## SPECIAL SENSES:

The eyes, middle and inner ears are not dissected.

## HEAD AND CENTRAL NERVOUS SYSTEM:

There is no subcutaneous or subgaleal hemorrhage in the scalp. The external periosteum and dura mater are stripped showing no fractures of the calvarium or base of the skull. There are no tears of the dura mater. There is no epidural, subdural or subarachnoid hemorrhage. The brain weighs 1390 grams. The leptomeninges are thin and transparent. A normal convolutionary pattern is observed. Coronal sectioning demonstrates a uniformity of cortical gray thickness. The cerebral hemispheres are symmetrical. There is no softening, discoloration or hemorrhage of the white matter. The basal ganglia are intact. Anatomic landmarks are preserved. Cerebral contusions are not present. The ventricular system is unremarkable without dilation or distortion. Pons, medulla and cerebellum are unremarkable. There is no evidence of uncal or cerebellar herniation. Vessels at the base of the brain have a normal pattern of distribution. There are no aneurysms. The cranial nerves are intact, symmetrical, and normal in size, location and course. The cerebral arteries are without arteriosclerosis.



**12****AUTOPSY REPORT**

No.

2010-01701

HAIM, COREY

Page 7

## SPINAL CORD:

The entire cord is not dissected.

## HISTOLOGIC SECTIONS:

Representative sections from various organs are preserved in one storage jar in 10% formalin.

## TOXICOLOGY:

Bile, blood, liver tissue, stomach contents, urine and vitreous humor have been submitted to the laboratory. A comprehensive screen was requested.

## PHOTOGRAPHY:

Photographs have been taken prior to the course of the autopsy.

## RADIOLOGY:

The body is fluoroscoped, and x-rays are taken of the head, pelvis, and lower extremities.

## WITNESSES:

Dr. Christopher Rogers.

## DIAGRAMS USED:

Diagram Forms 20 and 30 were used during the performance of the autopsy. The diagrams are not intended to be facsimiles.

**12****AUTOPSY REPORT**

No.

2010-01701

HAIM, COREY

Page 8

## OPINION:

The cause of death is diffuse alveolar damage due to community acquired pneumonia. Autopsy also revealed an enlarged heart weighing 530 grams (normal average weight is 300 grams) and biventricular hypertrophy of the ventricles. Also identified is an atherosclerotic plaque of the anterior descending branch of the left coronary artery.

Toxicology results of the blood show the presence of the following medications: dextromethorphan, diphenhydramine, ibuprofen, fluoxetine, olanzapine, diazepam, carisoprodol and meprobamate. These medications are present in low levels and are non-contributory to death. Also present is tetrahydrocannabinol in low levels.

There is no evidence of injury. The medications did not contribute acutely to his death therefore the manner of death is natural. Consultation is obtained with the Chief Medical Examiner-coroner, Chief, Forensic Medicine and Supervising Criminalist.

  
\_\_\_\_\_  
JUAN M. CARRILLO, M.D.  
DEPUTY MEDICAL EXAMINER

DATE

5/9/2010

JMC:mtm:c/f  
D-3/11/10  
T-3/18/10



**14**

I performed a microscopic examination on →

4/30/2010at THE DEPARTMENT OF CORONERLos Angeles, California

2010-01701


HAIM, COREY

MICROSCOPIC REVIEW

1. Cerebral cortex (Slide 2010-1701-1) Unremarkable. No evidence of inflammation of the meninges.
2. Lung (Slide 2010-1701-2,3,4) Examination of the lung tissue reveals alveolar walls lined by hyaline membranes. The alveolar spaces contain abundant macrophages, some consistent with carbon laden macrophages and scattered hemosiderin laden macrophages. A focal area shows abundant polymorphonuclear leukocytes in the alveolar space. Anthracotic pigment is present in the peribronchial interstitial tissue. Abundant congestion of the blood vessels noted. Special stains for micro-organisms is negative.
3. Liver (Slide 2010-01701-5) Sections of liver shows a normal architecture without bridging fibrosis.
4. Kidneys (Slide 2010-1701-6) Sections of renal parenchyma shows numerous obliterated hyalinized glomeruli. Occasional calcified material is noted in a renal tubule. No evidence of inflammatory cell infiltrate noted.
5. Heart (Slide 2010-1701-7,8,9,10) Examination of a section of the proximal left anterior descending branch of the left coronary artery reveals an atherosclerotic plaque narrowing the lumen to approximately 75%. The plaque shows a fibrous cap with centrally located calcification. No cholesterol clefts present and no evidence of thrombosis noted. There is a focal area of chronic inflammatory cell infiltration of the epicardium of the distal left ventricle consisting of lymphocytes. It does not extend into the myocardium. The adjacent myocardium shows extensive myofiber disarray. The myocardium of the left ventricle shows hypertrophic changes including enlarged myocardial nuclei.

Diagnosis: Heart: Coronary artery atherosclerosis  
 75% narrowing  
 Focal chronic epicarditis  
 Hypertrophic changes  
 Lungs: Diffuse alveolar damage  
 Focal acute pneumonia  
 Kidneys: Nephrosclerosis

Consultation obtained with Pathologist Dr. Koss of LAC/USC Medical Center.

  
 JUAN M. CARRILLO, M.D.  
 DEPUTY MEDICAL EXAMINER

5/4/2010  
 DATE

JMC:mtm/f  
 t-5/3/10

15

AUTOPSY CLASS:  A  B  C  Examination Only D

FAMILY OBJECTION TO AUTOPSY

Date: 3/11/2010 Time: 9:00 Dr. *Carrillo*

(Print)

FINAL ON: 4/30/2010 By: *Carrillo*

(Print)

APPROXIMATE INTERVAL BETWEEN ONSET AND DEATH

2010-01701  
HAIN, COREY  
ACC

DEATH WAS CAUSED BY: (Enter only one cause per line for A, B, C, and D)

IMMEDIATE CAUSE:

(A) *Diffuse alveolar damage*

DUE TO, OR AS A CONSEQUENCE OF:

(B) *Community acquired pneumonia*

DUE TO, OR AS A CONSEQUENCE OF:

(C)

DUE TO, OR AS A CONSEQUENCE OF:

(D)

OTHER CONDITIONS CONTRIBUTING BUT NOT RELATED TO THE IMMEDIATE CAUSE OF DEATH:

*Hypertrophic Cardiomyopathy with coronary arteriosclerosis*

NATURAL  SUICIDE  HOMICIDE

ACCIDENT  COULD NOT BE DETERMINED

If other than natural causes, HOW DID INJURY OCCUR?

WAS OPERATION PERFORMED FOR ANY CONDITION STATED ABOVE:  YES  NO

TYPE OF SURGERY: \_\_\_\_\_ DATE: \_\_\_\_\_

ORGAN PROCUREMENT  TECHNICIAN: *Simoney*  
 PREGNANCY IN LAST YEAR  YES  NO  UNK  NOT APPLICABLE

WITNESS TO AUTOPSY  EVIDENCE RECOVERED AT AUTOPSY  
Item Description: \_\_\_\_\_

*38 y.o. caucas. male collapsed at home -  
1st of flu-like symptoms. On multiple medications*

*Dr. Rogers witnessed autopsy*

Age: *38* Gender:  Male  Female  
PRIOR EXAMINATION REVIEW BY DME

BODY TAG  CLOTHING  
 X-RAY (No. *15*)  FLUORO  
 SPECIAL PROCESSING TAG  MED. RECORDS  
 AT SCENE PHOTOS (No. \_\_\_\_\_)

CASE CIRCUMSTANCES  
 EMBALMED  
 DECOMPOSED  
 >24 HRS IN HOSPITAL  
 OTHER: \_\_\_\_\_ (Reason)

TYPING SPECIMEN  
TYPING SPECIMEN TAKEN BY: \_\_\_\_\_  
SOURCE: \_\_\_\_\_

TOXICOLOGY SPECIMEN  
COLLECTED BY: \_\_\_\_\_  
 HEART BLOOD  STOMACH CONTENTS  
 FEMORAL BLOOD  VITREOUS X2  
TECHNIQUE: *1u, 2u*  
 \_\_\_\_\_ BLOOD  SPLEEN  
 \_\_\_\_\_ BLOOD  KIDNEY  
 BILE  \_\_\_\_\_  
 LIVER  \_\_\_\_\_  
 URINE  \_\_\_\_\_  
URINE GLUCOSE DIPSTICK RESULT: 4+ 3+ 2+ 1+ 0  
TOX SPECIMEN RECONCILIATION BY: *AJ*

HISTOLOGY  
 Regular (No. *1*)  Oversize (No. \_\_\_\_\_)  
Histopath Cut:  Autopsy  Lab

TOXICOLOGY REQUESTS  
FORM 3A:  YES  NO  
 NO TOXICOLOGY REQUESTED  
SCREEN  C  H  T  S  D  
 ALCOHOL ONLY  
 CARBON MONOXIDE  
 OTHER (Specify drug and tissue)

REQUESTED MATERIAL ON PENDING CASES  
 POLICE REPORT  MED HISTORY  
 TOX FOR COD  HISTOLOGY  
 TOX FOR R/O  INVESTIGATIONS  
 MICROBIOLOGY  EYE PATH. CONS.  
 RADIOLOGY CONS.  
 CONSULT ON: \_\_\_\_\_  
 BRAIN SUBMITTED  
 NEURO CONSULT  DME TO CUT  
 CRIMINALISTICS  
 GSR  SEXUAL ASSAULT  OTHER

RESIDENT

*[Signature]*  
DME



16

2010-01701  
MAIN, COREY  
ACC

SC

EXTERNAL EXAM

Sex  
Race  
Age  
Height  
Weight  
Hair  
Eyes  
Sclera  
Teeth  
Mouth  
Tongue  
Nose  
Chest  
Breasts  
Abdomen  
Scar  
Genitals  
Edema  
Skin  
Decubitus

HEART Wt. 530

Pericardium RV 0.7  
Hypertrophy  
Dilation LV 2.0  
Muscle 7-12.3 Septum 1.7  
Valves 8-6.7  
Coronaries 6.1

AORTA upid streaking

VESSELS

LUNGS Wt. R 1370 Heavy, congested  
L 1230 abundant edema  
Adhesions no consolidation  
Fluid no P.E.  
Atelectasis  
Oedema  
Congestion  
Consolidation  
Bronchi  
Nodes

PHARYNX clear  
TRACHEA  
THYROID  
THYMUS  
LARYNX  
HYOID

ABDOMINAL WALL FAT

PERITONEUM

Fluid  
Adhesions  
LIVER Wt. 2940  
Capsule  
Lobules  
Fibros  
GB 10 cc  
Calculus  
Bile ducts

SPLEEN Wt. 290

Color  
Consistency  
Capsule  
Malignant

PANCREAS

ADRENALS

KIDNEYS Wt.

R 190  
L 220  
Capsule  
Cortex  
Vessels  
Pelvis  
Ureters

BLADDER 50 cc amber urine

GENITALIA

Prostate  
Testes  
Uterus  
Tubes  
Ovaries

OESOPHAGUS

STOMACH 450 cc green fluid  
Contents

DUOD. & SM. INT. no pills

APPENDIX

LARGE INT. no pills

ABDOM. NODES

SKELETON

Spine  
Marrow  
Rib Cage  
Long bones  
Pelvis

SCALP

CALVARIUM

BRAIN Wt. 1390

Dura  
Fluid  
Ventricles  
Vessels  
Middle ears  
Other

PITUITARY

SPINAL CORD

TOXICOLOGY SPECIMENS

Blood Urine  
Urine Vitreous  
Stomach

SECTIONS FOR HISTOPATHOLOGY

1 - Brain 5 Liver 9-LV/10  
2 - Lung 6 Kidney 10-RV  
3 - es 7 LAD Mar  
4 - R lung 8 LAD Distal

MICROBIOLOGY

- Nasal swab  
- Lung swab  
- Blood cultures

DIAGRAMS

X-RAYS (+) healed fracture of leg

OTHER PROCEDURES

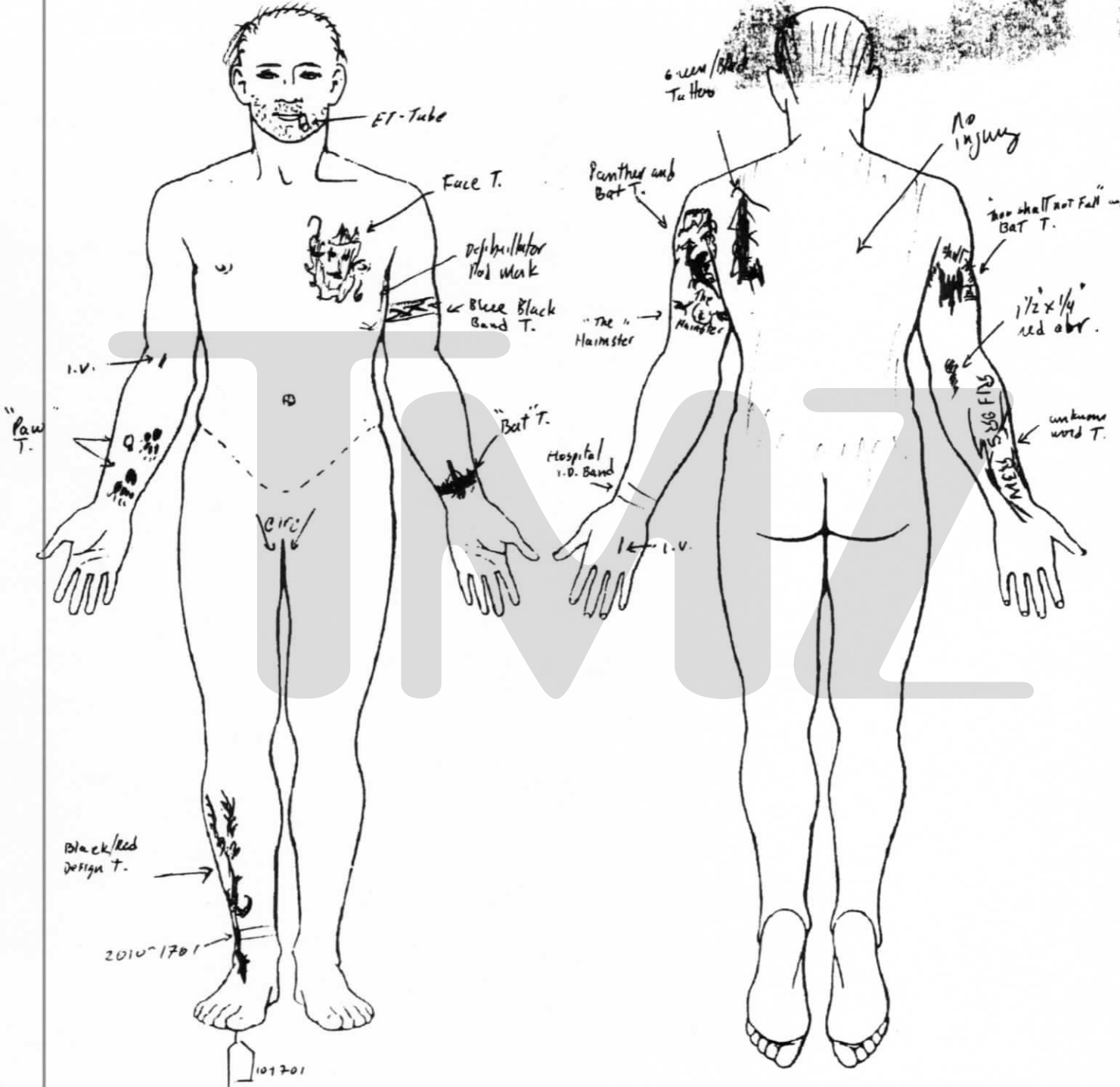
GROSS IMPRESSIONS

- 1. Cardiomegaly / ascites
- 2. Congestion / edema of lung
- 3. Hepatomegaly

Date 3/11/2010 Time 9:00 Deputy Medical Examiner [Signature]

20

2010-01701  
HAIN, COREY  
ACC  
SC



T. = Tattoos  
(Rev. 7/09)

Date \_\_\_\_\_

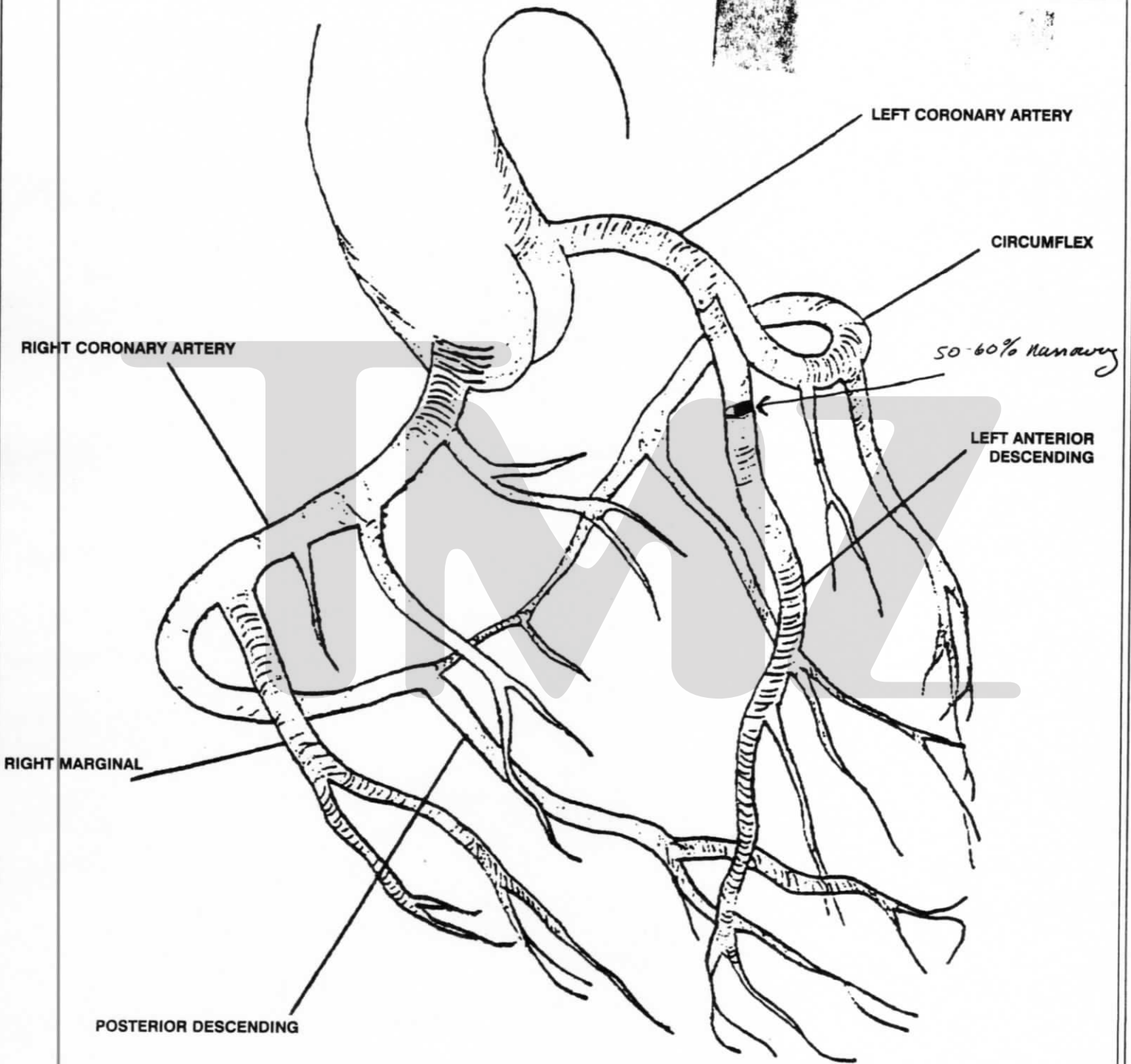
*[Signature]* 3/11/20.0 1ER M.D.  
Deputy Medical Examiner



30

2010-01701  
HAIN, COREY  
ACC

SC



Date

*[Signature]* 3/11/2010  
Deputy Medical Examiner

M.D.



Department of Coroner, County of Los Angeles  
**FORENSIC SCIENCE LABORATORIES**  
**Laboratory Analysis Summary Report**



To: Dr. Carrillo  
**Deputy Medical Examiner**

PendingTox

The following results have been technically and administratively reviewed and are the opinions and interpretations of the Analyst:

**Coroner Case Number: 2010-01701 Decedent: HAIM, COREY**

<u>SPECIMEN</u>	<u>SERVICE</u>	<u>DRUG</u>	<u>LEVEL</u>	<u>UNITS</u>	<u>ANALYST</u>
Blood, Heart					
	Acetaminophen	Acetaminophen	ND		O. Pleitez
	Alcohol	Ethanol	Negative		M. Schuchardt
	Barbiturate	Barbiturates	ND		J. Lintemoot
	Bases	Dextromethorphan	< 0.50	ug/ml	S. DeQuintana
	Bases	Diazepam	Present		S. DeQuintana
	Bases	Diphenhydramine	< 0.50	ug/ml	S. DeQuintana
	Bases	Fluoxetine	< 0.25	ug/ml	S. DeQuintana
	Bases	Haloperidol	ND		S. DeQuintana
	Bases	Nordiazepam	Present		S. DeQuintana
	Bases	Norfluoxetine	0.77	ug/ml	S. DeQuintana
	Bases	Olanzapine	< 0.10	ug/ml	S. DeQuintana
	Benzodiazepines	Diazepam	0.21	ug/ml	S. DeQuintana
	Benzodiazepines	Nordiazepam	0.26	ug/ml	S. DeQuintana
	Carbon Monoxide	Carbon Monoxide	< 10	% Saturation	M. Schuchardt
	Cocaine	Cocaine and Metabolites	ND		J. Lintemoot
	Cyanide	Cyanide	ND		M. Schuchardt
	ELISA	Oxycodone	ND		J. Lintemoot
	ELISA	Oxymorphone	ND		J. Lintemoot
	ELISA	Salicylate	ND		J. Lintemoot
	Fentanyl	Fentanyl	ND		J. Lintemoot
	Halogenated Hydrocarbons	Ethchlorvynol	ND		S. DeQuintana
	Halogenated Hydrocarbons	Trichlorethanol	ND		S. DeQuintana
	Marijuana	Carboxy-THC	55	ng/ml	B. Waters
	Marijuana	Tetrahydrocannabinol (THC)	< 2.5	ng/ml	B. Waters
	Methamphetamine	Methamphetamine	ND		J. Lintemoot
	Neutrals	Carisoprodol	< 2.5	ug/ml	O. Pleitez
	Neutrals	Ibuprofen	< 2.5	ug/ml	O. Pleitez
	Neutrals	Meprobamate	8.9	ug/ml	O. Pleitez
	Opiates	Codeine, Total	ND		S. Brooks

4/23/2010  
*f*

*ID*  
4/23/2010




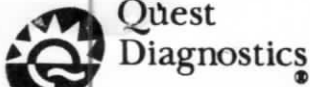
**Coroner Case Number: 2010-01701 Decedent: HAIM, COREY**

<u>SPECIMEN</u>	<u>SERVICE</u>	<u>DRUG</u>	<u>LEVEL</u>	<u>UNITS</u>	<u>ANALYST</u>
	Opiates	Hydrocodone, Total		ND	S. Brooks
	Opiates	Morphine, Total		ND	S. Brooks
	Outside Test	Hemoglobin A1C		Done	Quest Diagnostics
	Phencyclidine	Phencyclidine		ND	J. Lintemoot
	Volatiles	Acetone		ND	M. Schuchardt
	Volatiles	Isopropanol		ND	M. Schuchardt
<b>Urine</b>					
	"Dipstick"	Glucose		Negative	J. Muto
	Bases	Fluoxetine		Present	S. DeQuintana
	Bases	Norfluoxetine		Present	S. DeQuintana
	Bases	Olanzapine		Present	S. DeQuintana
<b>Vitreous</b>					
	Outside Test	Electrolytes		Done	NMS Labs, Inc.
	Outside Test	Glucose		45 mg/dL	NMS Labs, Inc.

**Legend:**

%	of total Hgb	ND	Not Detected
g%	gram percent (g/100ml)	ng/ml	Nanogram per Milliliter
mg	Milligram	ug/g	Microgram per Gram
mg/dL	milligrams per deciliter	ug/ml	Microgram per Milliliter

4/27/2010  
  
**Administratively reviewed by: Daniel T. Anderson M.S., FTS-ABFT, D-ABC**  
**Supervising Criminalist II**  
**TOXICOLOGY**



QUEST DIAGNOSTICS INCORPORATED  
CLIENT SERVICE 800.877.2515

SPECIMEN INFORMATION  
SPECIMEN: EN944338V  
REQUISITION: 8443670

COLLECTED: 04/16/2010 13:00 PT  
RECEIVED: 04/17/2010 04:02 PT  
REPORTED: 04/19/2010 06:57 PT

PATIENT INFORMATION  
**HAIM, COREY**

DOB: AGE:  
GENDER: FASTING: U

ID: 2010-01701  
PHONE:

REPORT STATUS **FINAL**

ORDERING PHYSICIAN


CLIENT INFORMATION  
W90033076 TZ24000  
EXAMINER OFFICE (CORONER)  
FORENSIC LABORATORY  
1104 N MISSION RD  
LOS ANGELES, CA 90033-1017

Test Name	In Range	Out of Range	Reference Range	Lab
HEMOGLOBIN Alc		5.7 H	<5.7 % of total Hgb	EN
	Increased risk for diabetes			
	<5.7 Non-diabetic			
	5.7-6.4 Increased risk for diabetes			
	> or = 6.5 Consistent with diabetes			

Standards of Medical Care in Diabetes-2010.  
Diabetes Care, 33(Supp 1): S1-S61,2010.

**PERFORMING LABORATORY INFORMATION**

EN QUEST DIAGNOSTICS-WEST HILLS, 8401 FALLBROOK AVENUE, WEST HILLS, CA 91304-3226, Laboratory Director: LEE H. HILBORNE, MD  
CLIA: 05D0642827



HAIM, COREY - EN944338V

Page 1 - End of Report

4/27/2010  
f  
04-27-10  
WJ



NMS Labs

CONFIDENTIAL

3701 Welsh Road, PO Box 433A, Willow Grove, PA 19090-0437
Phone: (215) 657-4900 Fax: (215) 657-2972
e-mail: nms@nmslabs.com

Robert A. Middleberg, PhD, DABFT, DABCC-TC, Laboratory Director

Toxicology Report

Report Issued 04/23/2010 10:00

Patient Name HAIM, COREY
Patient ID 2010-01701
Chain 11110689
Age Not Given
Gender Not Given
Workorder 10090301

Page 1 of 2

To: 10139
Los Angeles County Coroner Medical Examiner
Attn: Joseph Muto
1104 N. Mission Road
Los Angeles, CA 90033

Positive Findings:

Table with 4 columns: Compound, Result, Units, Matrix Source. Rows include Sodium (139 mEq/L), Potassium (12.8 mEq/L), Chloride (122 mEq/L), Creatinine (1.0 mg/dL), Urea Nitrogen (18 mg/dL), and Glucose (45 mg/dL).

See Detailed Findings section for additional information

Testing Requested:

Table with 2 columns: Analysis Code, Description. Rows include 1916FL (Electrolytes Panel, Fluid) and 7027FL (Glucose, Fluid).

Specimens Received:

Table with 5 columns: ID, Tube/Container, Volume/Mass, Collection Date/Time, Matrix Source, Miscellaneous Information. Row 1: 001 Red Top Tube, 1.75 mL, 04/15/2010 09:00, Vitreous Fluid.

All sample volumes/weights are approximations.
Specimens received on 04/16/2010.

Handwritten notes: 4/27/2010, 04-23-10, and initials.





CONFIDENTIAL

Workorder 10090301  
Chain 11110689  
Patient ID 2010-01701

Detailed Findings:

Analysis and Comments	Result	Units	Rpt. Limit	Specimen Source	Analysis By
Sodium	139	mEq/L		001 - Vitreous Fluid	[Not provided]
Potassium	12.8	mEq/L		001 - Vitreous Fluid	[Not provided]
Chloride	122	mEq/L		001 - Vitreous Fluid	[Not provided]
Creatinine	1.0	mg/dL		001 - Vitreous Fluid	[Not provided]
Urea Nitrogen	18	mg/dL		001 - Vitreous Fluid	[Not provided]
Glucose	45	mg/dL		001 - Vitreous Fluid	[Not provided]

Other than the above findings, examination of the specimen(s) submitted did not reveal any positive findings of toxicological significance by procedures outlined in the accompanying Analysis Summary.

Reference Comments:

- Glucose - Vitreous Fluid:  
Analysis for Glucose was performed by:  
Health Network Laboratories  
2024 Lehigh Street  
Allentown, PA 18103
- Urea Nitrogen - Vitreous Fluid:  
Analysis for Electrolytes Panel, including Sodium, Potassium, Chloride, Creatinine and Urea Nitrogen was performed by:  
Health Network Laboratories  
2024 Lehigh Street  
Allentown, PA 18103

Chain of custody documentation has been maintained for the analyses performed by NMS Labs.

Unless alternate arrangements are made by you, the remainder of the submitted specimens will be discarded six (6) weeks from the date of this report; and generated data will be discarded five (5) years from the date the analyses were performed.

Analysis Summary and Reporting Limits:

Acode 1916FL - Electrolytes Panel, Fluid - Vitreous Fluid

-Analysis by [Not provided] for:

<u>Compound</u>	<u>Rpt. Limit</u>	<u>Compound</u>	<u>Rpt. Limit</u>
Chloride	N/A	Sodium	N/A
Creatinine	N/A	Urea Nitrogen	N/A
Potassium	N/A		

Acode 7027FL - Glucose, Fluid - Vitreous Fluid

-Analysis by [Not provided] for:

<u>Compound</u>	<u>Rpt. Limit</u>	<u>Compound</u>	<u>Rpt. Limit</u>
Glucose	N/A		

*Handwritten signature and date: 4/23/2010*

COUNTY OF LOS ANGELES - DEPARTMENT OF PUBLIC HEALTH  
 PUBLIC HEALTH LABORATORY - 12750 ERICKSON AVENUE, DOWNEY, CA 90242  
 MARY BETH DUKE, M.S., ACTING DIRECTOR (562)658-1330

NAME: HAIM, COREY LOC: L.A. COUNTY CORONERS OFFICE  
 PATIENT ID# LACCO-201001701 DOB: 12/23/1971 AGE: 38Y SEX: M  
 REQ'D BY: REFERRED

COLLECTED: 03/11/2010 UNK RECEIVED: 03/11/2010 18:00  
 ACC. NO.: F37956 SUBM. ACC. NO.: DR.CAMLLO

TEST NAME	TEST RESULT	REFERENCE RANGE
LUMINEX *TAG RESPIRATORY VIRAL PANEL MULTIPLEX PCR		
INFLUENZA A	NOT DETECTED Result date,time:04/07/2010,15:24	
INFLUENZA A SUBTYPE H1	NOT DETECTED Result date,time:04/07/2010,15:24	
INFLUENZA A SUBTYPE H3	NOT DETECTED Result date,time:04/07/2010,15:24	
INFLUENZA B	NOT DETECTED Result date,time:04/07/2010,15:24	
RSV SUBTYPE A	NOT DETECTED Result date,time:04/07/2010,15:24	
RSV SUBTYPE B	NOT DETECTED Result date,time:04/07/2010,15:24	
PARAINFLUENZA 1	NOT DETECTED Result date,time:04/07/2010,15:24	
PARAINFLUENZA 2	NOT DETECTED Result date,time:04/07/2010,15:24	
PARAINFLUENZA 3	NOT DETECTED Result date,time:04/07/2010,15:24	
HUMAN METAPNEUMOVIRUS	NOT DETECTED Result date,time:04/07/2010,15:24	
RHINOVIRUS	NOT DETECTED Result date,time:04/07/2010,15:24	
ADENOVIRUS	NOT DETECTED Result date,time:04/07/2010,15:24	

DEPARTMENT OF  
 CORONER DOCUMENT

TEST NAME	TEST RESULT	REFERENCE RANGE
PANDEMIC AND SEASONAL INFLUENZA		

HAIM, COREY  
 CLIENT REPORT

CONTINUED  
 ACCOUNT NO.: LACCO PRINT DATE & TIME: 04/08/2010

PAGE 1  
 07:52

*Cornello*

COUNTY OF LOS ANGELES - DEPARTMENT OF PUBLIC HEALTH  
PUBLIC HEALTH LABORATORY - 12750 ERICKSON AVENUE, DOWNEY, CA 90242  
MARY BETH DUKE, M.S., ACTING DIRECTOR (562)658-1330

NAME: HAIM, COREY LOC: L.A. COUNTY CORONERS OFFICE  
PATIENT ID# LACCO-201001701 DOB: 12/23/1971 AGE: 38Y SEX: M  
REQ'D BY: REFERRED

COLLECTED: 03/11/2010 UNK RECEIVED: 03/11/2010 18:00  
ACC. NO.: F37956 SUBM. ACC. NO.: DR.CAMLLO

BY PCR

SPECIMEN OTHER  
DESCRIPTION NASOPHARYNX  
Result date,time:03/12/2010,10:23

INFLUENZA A  
ANALYZED BY ABI  
7500 FAST DX  
PANDEMIC INFLUENZA A AND SEASONAL INFLUENZA A NOT DETECTED BY RT-PCR.  
Result date,time:03/12/2010,14:21

ADDITIONAL COMMENTS

THE CONFIRMING TEST RESULTS WERE OBTAINED USING CDC REAGENTS PROVIDED UNDER AN EMERGENCY USE AUTHORIZATION (EUA). PLEASE REFER TO THE FDA FACTSHEETS REGARDING THIS EUA TEST.

PLEASE SEE LINK TO FACT SHEETS REGARDING SWINE INFLUENZA TEST INTERPRETATION: <http://www.fda.gov/cdrh/emergency/panel-factsheet1.html> and <http://www.fda.gov/cdrh/emergency/panel-factsheet2.html>.  
Result date,time:03/12/2010,14:21

TEST NAME  
SEASONAL INFLUENZA B  
BY PCR

TEST RESULT

REFERENCE RANGE

SPECIMEN OTHER  
DESCRIPTION NASOPHARYNX  
Result date,time:03/18/2010,15:33

INFLUENZA B  
ANALYZED BY ABI  
7500 FAST DX  
INFLUENZA B VIRUS NOT DETECTED BY RT-PCR  
Result date,time:03/18/2010,15:33

ADDITIONAL COMMENTS

THE CONFIRMING TEST RESULTS WERE OBTAINED USING CDC REAGENTS PROVIDED UNDER AN EMERGENCY USE AUTHORIZATION (EUA). PLEASE REFER TO THE FDA FACTSHEETS REGARDING THIS EUA TEST.

PLEASE SEE LINK TO FACT SHEETS REGARDING SWINE INFLUENZA TEST INTERPRETATION: <http://www.fda.gov/cdrh/emergency/panel-factsheet1.html> and <http://www.fda.gov/cdrh/emergency/panel-factsheet2.html>.  
Result date,time:03/18/2010,15:33

DEPARTMENT OF  
CORONER DOCUMENT

HAIM, COREY  
CLIENT REPORT

END OF REPORT  
ACCOUNT NO.: LACCO PRINT DATE & TIME: 04/08/2010 07:52

PAGE 2

*Camllo*



COUNTY OF LOS ANGELES - DEPARTMENT OF PUBLIC HEALTH  
PUBLIC HEALTH LABORATORY - 12750 ERICKSON AVENUE, DOWNEY, CA 90242  
MARY BETH DUKE, M.S., ACTING DIRECTOR (562)658-1330

NAME: HAIM, COREY LOC: L.A. COUNTY CORONERS OFFICE  
PATIENT ID# LACCO-201001701 DOB: 12/23/1971 AGE: 38Y SEX: M  
REQ'D BY: REFERRED

COLLECTED: 03/11/2010 UNK RECEIVED: 03/11/2010 18:00  
ACC. NO.: F37956 SUBM. ACC. NO.: DR.CAMLLO

TEST NAME	TEST RESULT	REFERENCE RANGE
<b>PANDEMIC AND SEASONAL INFLUENZA BY PCR</b>  SPECIMEN DESCRIPTION  INFLUENZA A ANALYZED BY ABI 7500 FAST DX	OTHER NASOPHARYNX <i>Result date, time: 03/12/2010, 10:23</i>  PANDEMIC INFLUENZA A AND SEASONAL INFLUENZA A NOT DETECTED BY RT-PCR. <i>Result date, time: 03/12/2010, 14:21</i>	
ADDITIONAL COMMENTS	THE CONFIRMING TEST RESULTS WERE OBTAINED USING CDC REAGENTS PROVIDED UNDER AN EMERGENCY USE AUTHORIZATION (EUA). PLEASE REFER TO THE FDA FACTSHEETS REGARDING THIS EUA TEST.  PLEASE SEE LINK TO FACT SHEETS REGARDING SWINE INFLUENZA TEST INTERPRETATION: <a href="http://www.fda.gov/cdrh/emergency/panel-factsheet1.html">http://www.fda.gov/cdrh/emergency/panel-factsheet1.html</a> and <a href="http://www.fda.gov/cdrh/emergency/panel-factsheet2.html">http://www.fda.gov/cdrh/emergency/panel-factsheet2.html</a> . <i>Result date, time: 03/12/2010, 14:21</i>	

TEST NAME	TEST RESULT	REFERENCE RANGE
<b>SEASONAL INFLUENZA B BY PCR</b>  SPECIMEN DESCRIPTION  INFLUENZA B ANALYZED BY ABI 7500 FAST DX	OTHER NASOPHARYNX <i>Result date, time: 03/18/2010, 15:33</i>  INFLUENZA B VIRUS NOT DETECTED BY RT-PCR <i>Result date, time: 03/18/2010, 15:33</i>	
ADDITIONAL COMMENTS	THE CONFIRMING TEST RESULTS WERE OBTAINED USING CDC REAGENTS PROVIDED UNDER AN EMERGENCY USE AUTHORIZATION (EUA). PLEASE REFER TO THE FDA FACTSHEETS REGARDING THIS EUA TEST.  PLEASE SEE LINK TO FACT SHEETS REGARDING SWINE INFLUENZA TEST	

HAIM, COREY CONTINUED PAGE 1  
CLIENT REPORT ACCOUNT NO.: LACCO PRINT DATE & TIME: 03/23/2010 07:52

**DEPARTMENT OF CORONER DOCUMENT**

*Camllo*

*3/31/2010*

COUNTY OF LOS ANGELES - DEPARTMENT OF PUBLIC HEALTH  
PUBLIC HEALTH LABORATORY - 12750 ERICKSON AVENUE, DOWNEY, CA 90242  
MARY BETH DUKE, M.S., ACTING DIRECTOR (562) 658-1330

NAME: HAIM, COREY LOC: L.A. COUNTY CORONERS OFFICE  
PATIENT ID# LACCO-201001701 DOB: 12/23/1971 AGE: 38Y SEX: M  
REQ'D BY: REFERRED

COLLECTED: 03/11/2010 UNK RECEIVED: 03/11/2010 18:00  
ACC. NO.: F37956 SUBM. ACC. NO.: DR.CAMLLO

TEST NAME	TEST RESULT	REFERENCE RANGE
SEASONAL INFLUENZA B BY PCR	(CONTINUED)	
ADDITIONAL COMMENTS	(CONTINUED)	
	<i>Result date,time:03/18/2010,15:33</i> INTERPRETATION: <a href="http://www.fda.gov/cdrh/emergency/panel-factsheet1.html">http://www.fda.gov/cdrh/emergency/panel-factsheet1.html</a> and <a href="http://www.fda.gov/cdrh/emergency/panel-factsheet2.html">http://www.fda.gov/cdrh/emergency/panel-factsheet2.html</a> . <i>Result date,time:03/18/2010,15:33</i>	



DEPARTMENT OF  
CORONER DOCUMENT

*Camillo*

LAC + USC Medical Center  
 1200 N. State St., Los Angeles, CA 90033  
 Ira A. Shulman, M.D., Director, Laboratories & Pathology  
 03/14/2010 07:00

Page: 1

H444792 COLL: 03/11/2010 0930 REC: 03/11/2010 1806 PHYS: ILLEGIBLE, PHYSICIAN  
 WOUND CULT, AEROBIC FINAL 03/13/2010  
 MICRO LAB SETUP: UNKNOWN UNKNOWN

SPECIMEN DESCRIPTION: LUNG  
 SPECIAL REQUESTS: NONE

GRAM STAIN: Cell debris  
 1+ POLYMORPHONUCLEAR LEUKOCYTES  
 2+ MONONUCLEAR CELLS  
 RED BLOOD CELLS  
 NO ORGANISMS SEEN

CULTURE: NO GROWTH AT 48 HRS.

H445331 COLL: 03/11/2010 0930 REC: 03/11/2010 2135 PHYS: ILLEGIBLE, PHYSICIAN  
 BLOOD CULTURE - AERO FINAL 03/13/2010  
 MICRO LAB SETUP: 03112010 2141

SPECIMEN DESCRIPTION: BLOOD  
 SPECIAL REQUESTS: NONE

CULTURE: Staphylococcus epidermidis

H445332 COLL: 03/11/2010 0930 REC: 03/11/2010 2135 PHYS: ILLEGIBLE, PHYSICIAN  
 BLOOD CULTURE - ANAE \*\*\* PRELIMINARY \*\*\*  
 MICRO LAB SETUP: 03112010 2141

SPECIMEN DESCRIPTION: BLOOD  
 SPECIAL REQUESTS: NONE

CULTURE: NO GROWTH 2 DAYS

## DEPARTMENT OF CORONER DOCUMENT

END OF REPORT

ACCOUNT #: 9068

CONFIDENTIAL  
 SUMMARY REPORT

HAIM, COREY  
 CC-201001701  
 CC CORONERS CASE  
 M 12/23/1971

*Corey Haim*



COUNTY OF LOS ANGELES - DEPARTMENT OF PUBLIC HEALTH  
PUBLIC HEALTH LABORATORY - 12750 ERICKSON AVENUE, DOWNEY, CA 90242  
MARY BETH DUKE, M.S., ACTING DIRECTOR (562) 658-1330

NAME: HAIM, COREY

1701

LOC: L.A. COUNTY CORONERS OFFI

PATIENT ID# LACCO-2010017

DOB: 12/23/1971

AGE: 38Y

SEX: M

REQ'D BY: REFERRED OTH. CLINICIAN:

F37956 COLL: 03/11/2010 UNKNOWN REC: 03/11/2010 18:00 PHYS: REFERRED

DR. CAMLLO

PANDEMIC AND SEASONAL INFLUENZA BY PCR

SPECIMEN DESCRIPTION OTHER

NASOPHARYNX

INFLUENZA A ANALYZED BY ABI 7500 FAST DX

PANDEMIC INFLUENZA A AND SEASONAL INFLUENZA

A NOT DETECTED BY RT-PCR.

ADDITIONAL COMMENTS

THE CONFIRMING TEST RESULTS WERE OBTAINED  
USING CDC REAGENTS PROVIDED UNDER AN  
EMERGENCY USE AUTHORIZATION (EUA).  
PLEASE REFER TO THE FDA FACTSHEETS  
REGARDING THIS EUA TEST.

PLEASE SEE LINK TO FACT SHEETS REGARDING  
SWINE INFLUENZA TEST INTERPRETATION:

<http://www.fda.gov/cdrh/emergency/panel-factsheet1.html> and

<http://www.fda.gov/cdrh/emergency/panel-factsheet2.html>.

SEASONAL INFLUENZA B BY PCR

SPECIMEN DESCRIPTION OTHER

NASOPHARYNX

INFLUENZA B ANALYZED BY ABI 7500 FAST DX

INFLUENZA B VIRUS NOT DETECTED BY RT-PCR

ADDITIONAL COMMENTS

THE CONFIRMING TEST RESULTS WERE OBTAINED  
USING CDC REAGENTS PROVIDED UNDER AN  
EMERGENCY USE AUTHORIZATION (EUA).  
PLEASE REFER TO THE FDA FACTSHEETS  
REGARDING THIS EUA TEST.

PLEASE SEE LINK TO FACT SHEETS REGARDING  
SWINE INFLUENZA TEST INTERPRETATION:

<http://www.fda.gov/cdrh/emergency/panel-factsheet1.html> and

<http://www.fda.gov/cdrh/emergency/panel-factsheet2.html>.

DEPARTMENT OF  
CORONER DOCUMENT

HAIM, COREY

ACCOUNT NO: LACCO

END OF REPORT

INTERIM REPORT

REPORT DATE AND TIME: 03/22/2010 08:33

PAGE 1

*Camillo*  
3/31/2010  
F

COUNTY OF LOS ANGELES - DEPARTMENT OF PUBLIC HEALTH  
PUBLIC HEALTH LABORATORY - 12750 ERICKSON AVENUE, DOWNEY, CA 90242  
MARY BETH DUKE, M.S., ACTING DIRECTOR (562)658-1330

NAME: HAIM, COREY 2010-1701 LOC: L.A. COUNTY CORONERS OFFICE  
PATIENT ID# LACCO-201001201 DOB: 12/23/1971 AGE: 38Y SEX: M  
REQ'D BY: REFERRED

COLLECTED: 03/11/2010 UNK RECEIVED: 03/11/2010 18:00  
ACC. NO.: F37956 SUBM. ACC. NO.:

TEST NAME	TEST RESULT	REFERENCE RANGE
SEASONAL INFLUENZA B BY PCR	(CONTINUED)	
ADDITIONAL COMMENTS	(CONTINUED)	
	Result date,time:03/18/2010 ,15:33	
	INTERPRETATION: <a href="http://www.fda.gov/cdrh/emergency/panel-factsheet1.html">http://www.fda.gov/cdrh/emergency/panel-factsheet1.html</a>	
	and <a href="http://www.fda.gov/cdrh/emergency/panel-factsheet2.html">http://www.fda.gov/cdrh/emergency/panel-factsheet2.html</a> .	
	Result date,time:03/18/2010 ,15:33	



# DEPARTMENT OF CORONER DOCUMENT

HAIM, COREY  
CLIENT REPORT

ACCOUNT NO.: LACCO

END OF REPORT  
PRINT DATE & TIME: 03/19/2010

PAGE 2  
07:52

*Selser*  
*Canillo*

*3-21-10*  
*29*

18

**TO REPORT A DEATH — PHONE (213) 343-0711**

COMPLETE ALL LINES. USE INK. IF UNKNOWN OR NOT APPLICABLE,  
SO STATE.

Providence Saint Joseph Medical Center  
NAME OF FACILITY

CC# JD10-01701

ADDRESS 501 South Buena Vista St, Burbank, CA 91505 PHONE (818) 847-4043

NAME OF DECEDENT HAIM, COREY I  
HOW IDENTIFIED Drivers license / Family DOB 12/23/71 AGE 38 SEX M RACE C  
DATE OF DEATH 3/10/2010 TIME 0215

PRONOUNCED BY Dr Biren, Pamela C MEDICAL RECORD OR PATIENT FILE # N000044826

EMERGENCY ROOM PATIENT

**ORGAN/TISSUE DONATION INFORMATION**

WAS THE NEXT-OF-KIN APPROACHED REGARDING ORGAN/TISSUE DONATION?

NO  YES  IF YES WHAT WAS THEIR RESPONSE? \_\_\_\_\_

HOSPITAL IN PATIENT

DATE ADMITTED 3-10-2010 TIME \_\_\_\_\_

TO HOSPITAL BY:  POLICE  RELATIVES  FRIENDS  SELF  AMBULANCE (Name or R.A. #) RA:60

FROM \_\_\_\_\_  
(STATE WHETHER HOME, HOSPITAL OR OTHER) GIVE ADDRESS \_\_\_\_\_ (IF HOSPITAL ATTACH THEIR HISTORY)

ADMITTED BY: \_\_\_\_\_ M.D. PRIMARY ATTENDING PHYSICIAN Biren M.D.

PHONE # \_\_\_\_\_ PHONE # \_\_\_\_\_

INJURIES \_\_\_\_\_ DATE \_\_\_\_\_ TIME \_\_\_\_\_ PLACE \_\_\_\_\_ CAUSE \_\_\_\_\_  
(TRAFFIC, FALL, ETC.)

DESCRIBE INJURIES: No Injuries Noted.

CLINICAL HISTORY: per EMS (RA-60) patient was prescribed Haldol 60 tabs on 3-9-10 - Empty Bottle found at Bedside.

SURGICAL PROCEDURES: STATE TYPE, DATE, TIME AND RESULTS OF ANY OPERATION OR AMPUTATION PERFORMED

N/A

ACCT N008283194 03/10/10

HAIM, COREY I 38/M  
Biren MD, Pamela C N. ED  
MR N000044826 DOB 12/23/71

WAS A BULLET OR OTHER FOREIGN OBJECT RECOVERED? SPECIFY N/A

LABORATORY: SPECIFY SPECIMENS TAKEN \_\_\_\_\_ DATE & TIME \_\_\_\_\_

LABORATORY RESULTS:

RETAIN LABORATORY SPECIMENS

X-RAY REPORT:

REMARKS: ESPECIALLY SYMPTOMS PRECEDING AND DURING TERMINAL EPISODE

IN MY OPINION, THE IMMEDIATE CAUSE OF DEATH IS: \_\_\_\_\_

BY \_\_\_\_\_ M.D. -OR- \_\_\_\_\_ NURSE/HOSPITAL ADMINISTRATOR

PHONE # \_\_\_\_\_