

1	APPARENT MODE SUICIDE	CASE NO 2012-00769
	SPECIAL CIRCUMSTANCES Celebrity, Gunshot Wound, Media Interest	CRYPT SEC

LAST, FIRST MIDDLE **CORNELIUS, DONALD** AKA #

ADDRESS [REDACTED] CITY **LOS ANGELES** STATE **CA** ZIP [REDACTED]

SEX MALE	RACE APPEARS BLACK	DOB 9/27/1936	AGE 75	HGT 72 in.	WGT 210 lbs.	EYES BROWN	HAIR GRAY	TEETH INCOMPLETE	FACIAL HAIR UNSHAVEN	ID VIEW Yes	CONDITION FAIR
--------------------	------------------------------	-------------------------	------------------	----------------------	------------------------	----------------------	---------------------	----------------------------	--------------------------------	-----------------------	--------------------------

MARK TYPE SCAR	MARK LOCATION ABDOMEN	MARK DESCRIPTION OLD HEALED INCISION
SCAR	RIGHT ANKLE	OLD HEALED INCISION

IDENTIFIED BY [REDACTED] PHONE [REDACTED] NOTIFIED BY [REDACTED] TIME **2/1/2012 05:00**

SSN **XXXX - XX - 1783** DL ID **C5585260** STATE **CA** PENDING BY [REDACTED]

ID METHOD **FINGERPRINTS FROM DOJ**

LA # [REDACTED] MAIN # **32950849** CII # **A24212265** FBI # **0109298Y1** MILITARY # [REDACTED] POB **CHICAGO, IL**

IDENTIFIED BY NAME (PRINT) [REDACTED] RELATIONSHIP [REDACTED] PHONE [REDACTED] DATE **2/1/2012** TIME **09:33**

PLACE OF DEATH / PLACE FOUND **HOSPITAL** ADDRESS OR LOCATION **8700 BEVERLY BLVD** CITY **LOS ANGELES** ZIP **90048**
CEDARS-SINAI MEDICAL CENTER

PLACE OF INJURY **RESIDENCE** AT WORK **No** DATE **2/1/2012** TIME **03:15** LOCATION OR ADDRESS [REDACTED] ZIP **90210**

ODD **2/1/2012** TIME **04:56** FOUND OR PRONOUNCED BY **DR. SALIM**

OTHER AGENCY INV. OFFICER **LAPD ROBBERY HOMICIDE DIVISION - DETECTI** PHONE **(213) 842-0788** REPORT NO. **INC. #0439** NOTIFIED BY [REDACTED] NO

TRANSPORTED BY **SERGIO FLORES** TO **LOS ANGELES FSC** DATE **2/1/2012** TIME **09:15**

FINGERPRINTS? Yes	CLOTHING Yes	PA RPT No	MORTUARY
MED. EV. No	INVEST. PHOTO # 8	SEAL TYPE	HOSP RPT Yes
PHYS. EV. Yes	EVIDENCE LOG Yes	PROPERTY? No	HOSP CHART Yes
SUICIDE NOTE No	GSR NO C7273	RCPT. NO. 257368	PF NO. 990002214

SYNOPSIS
 ACCORDING TO ALL OF THE REPORTED INFORMATION, ON 02/01/12, AT ABOUT 0300 HRS. THE DECEDENT(HIS FATHER). THE DECEDENT STATED THAT I DON'T THINK I'LL BE HERE LONG. RECEIVED A PHONE FROM [REDACTED], THEN DROVE TO HIS FATHERS HOME. HE FOUND THE BACK DOOR OPEN AND DETECTED THE ODOR OF SMOKE. HE THEN FOUND THE DECEDENT UNRESPONSIVE ON A CHAIR. 911 WAS DIALED. THE DECEDENT WAS TRANSPORTED TO THE HOSPITAL VIA AMBULANCE. DESPITE ALL LIFE SAVING MEASURES HE EXPIRED AT 0456 HRS. NO FOUL PLAY IS SUSPECTED. THE DECEDENT HAD BEEN DEPRESSED ABOUT FAILING HEALTH. NO NOTE WAS FOUND.

MARIO SAINZ 434184 *Mario Sainz* INVESTIGATOR DATE **2/2/2012** TIME **07:30** REVIEWED BY *[Signature]* DATE **2/2/12** TIME

FORM #3 NARRATIVE TO FOLLOW?



County of Los Angeles, Department of Coroner
Investigator's Narrative



Case Number: 2012-00769

Decedent: CORNELIUS, DONALD

Information Sources:

- 1) LAPD RHD Detective Myers. 213-842-0788.
- 2) Cedars-Sinai Medical Center report. 8700 Beverly Bl. Los Angeles, CA. 90048
- 3)

Investigation:

On 02/01/2012, at 0528 hours, hospital personnel Mario Roman reported an apparent suicide via gunshot wound to the head. On 02/01/2012, at 0655 hours, I was assigned this hospital death by Lt. Dietz. I was accompanied by Lt. MacWillie. We arrived at the hospital at 0805 hours. I concluded my hospital investigation at 0835 hours. Later in the afternoon I spoke with Detective Myers and [redacted] via telephone. No foul play is suspected. No note was found.

Location:

The original incident occurred at a residence located at 12685 Mulholland Drive Los Angeles, CA. 90210. The decedent was transported to the above listed hospital via ambulance.

Informant/Witness Statements:

On 02/01/2012, at about 1210 hours, I conducted a phone interview with Detective Myers who related the following; the decedent Donald Cornelius had suffered an aneurysm about 15 years ago. Due to the aneurysm the decedent developed seizures. As time went on the decedent's health continued to decline regardless of his medication. Within the past six months the decedent would have conversations with his son [redacted] and stated that he didn't know how much longer he could hang on. The decedent was very depressed about his failing health. On 02/01/2012, at about 0300 hours, the decedent telephoned his son [redacted] and stated that, I don't know how long I can take this. [redacted] / told him that I'll be right over. His father told him that the back door would be unlocked. When [redacted] arrived at the location he found the back door unlocked and detected an odor of smoke. [redacted] then found his father seated in a chair with a pistol in his right hand. He then dialed 911. Responding officers found one empty casing. The pistol was rendered safe. When asked, Detective Myers said that the hospital staff placed brown paper bags over the decedent's hands at the hospital.

According to the hospital report; on 02/01/2012, at about 0423 hours, the decedent was presented into the ER via ambulance. He was in full arrest with CPR in progress by paramedics. The decedent was found to have a through n through bullet wound to his head. Despite all life saving measures, Dr. Salim pronounced death at 0456 hours.

On 02/01/2012, at 1510 hours, I conducted a phone interview with [redacted] corroborated the same information I received from Detective Myers with the exception that he did not know his father owned a gun. No further information.

Scene Description:

Coroner personnel did not visit the scene.

Evidence:

On 02/01/2012, at 0817 hours, I collected GSR kit #C7273 at the hospital.



County of Los Angeles, Department of Coroner
Investigator's Narrative



Case Number: 2012-00769

Decedent: CORNELIUS, DONALD

Body Examination:

The decedent was a 75-year-old black male. He was observed supine on a hospital bed in the emergency room. He was covered with a white sheet. He was clad in black pants, black underwear and a white hospital gown. No tattoos were noted. I noted two old healed incisions to his abdomen and right ankle. He had been intubated. I saw an IV at the left antecubital. His hands were covered with brown paper bags. I noted petechia in his eyes. I found what appears to be a bullet entrance contact wound to the right temple. I saw what appears to be an exit wound to the upper left side of his head. No other trauma was noted.

Identification:

On 02/01/2012, at 0933 hours, DOJ prints identified the decedent as, Donald Cornelius.

Next of Kin Notification:

On 02/01/2012, at 0500 hours, hospital staff notified _____ father's death in person at the hospital.

Tissue Donation:

At the completion of my reports family did not give permission for tissue donations.

Autopsy Notification:

There is no request for an autopsy notification regarding this case.

INVESTIGATOR MARIO SAINZ
434184

LT. DIETZ


02/02/2012

Date of Report

12

AUTOPSY REPORT

No.
2012-00769
CORNELIUS, DONALD

I performed an autopsy on the body of 
the DEPARTMENT OF CORONER

at Los Angeles, California on FEBRUARY 3, 2012 @ 1030 HOURS
(Date) (Time)

From the anatomic findings and pertinent history I ascribe the death to:
GUNSHOT WOUND OF HEAD

- (A) DUE TO, OR AS A CONSEQUENCE OF
- (B) DUE TO, OR AS A CONSEQUENCE OF
- (C) DUE TO, OR AS A CONSEQUENCE OF
- (D) OTHER CONDITIONS CONTRIBUTING BUT NOT RELATED TO THE IMMEDIATE CAUSE OF DEATH:

Anatomical Summary:

- I. Contact gunshot wound of head.
 - A. Entry: Right temple.
 - B. Exit: Left parietal scalp.
 - C. Projectile: No projectile recovered at autopsy.
 - D. Direction: Right to left, upward, and slightly front to back.
 - E. Path: Involving scalp, skull and brain.
- II. Aneurysm of anterior communicating artery.
- III. History of craniotomy.
- IV. Two inferior vena cava filters.
 - A. Remote perforation of aorta.
- V. Atherosclerotic cardiovascular disease.
- VI. Multicystic kidneys.
- VII. Mild bullous emphysema.
- VIII. Nodular prostatic hyperplasia.
- IX. Bilateral hydroceles.

12**AUTOPSY REPORT**

No.

2012-00769

CORNELIUS, DONALD

Page 2

- X. Evidence of therapy:
- A. Endotracheal tube.
 - B. Fractures of both 4th ribs.

CIRCUMSTANCES:

The decedent is a 75-year-old man found deceased at his residence. He had a history of depression.

DESCRIPTION OF GUNSHOT WOUND:

Entry: The entry wound is located on the right temple, 2-1/2 inches below the top of the head and 2-3/4 inches right of the midline. It consists of a 3/8 inch roughly round defect with a 1/2 inch laceration at 4 o'clock. It is completely surrounded by a 1/8 to 1/4 inch zone of abrasion. There is a 1/32 inch zone of sooting at 4 to 5 o'clock.

Exit: The exit wound is located on the left parietal scalp, 1-1/2 inches below the top of the head and 2 inches left of the midline. It consists of a stellate wound with a 1 inch laceration at 2 o'clock, a 1-1/2 inch laceration at 4 o'clock, a 1/2 inch laceration at 6 o'clock, a 1-1/4 inch laceration at 9 o'clock, and a 1/2 inch laceration at 11 o'clock.

Projectile: No projectile is recovered at autopsy.

Direction: Right to left, upward, and slightly front to back.

Course: The hemorrhagic wound track penetrates the skin of the right temple, resulting in soot deposition on the margin of the wound, margin of the skull, and margin of the dura. The skull in this area shows inner table beveling. The projectile passes through the right cerebral hemisphere and exits the skull and scalp through the left parietal scalp. There is outer table beveling in this area.

12**AUTOPSY REPORT**

No.

2012-00769

CORNELIUS, DONALD

3

Page _____

EXTERNAL EXAMINATION:

The body is identified by toe tags and is that of an unembalmed, refrigerated adult African-American male who appears about the stated age of 75 years. The body weighs 210 pounds, measures 72 inches in length, and is mildly obese.

The skin is free of abrasions, bruises, lacerations and burns. Tattoos are not present. Rigor mortis is present in the limbs and jaw. Livor mortis is fixed and distributed posteriorly.

The head is normocephalic and partly covered by gray hair. There is frontal balding. Mustache and beard are absent. Examination of the eyes reveals brown irides and sclerae that show no injection or jaundice. There are no petechial hemorrhages of the conjunctivae of the lids or the sclerae. The oronasal passages are unobstructed. Upper and lower teeth are present. Dentures are not identified. The neck is unremarkable. There is no chest deformity. There is no increase in the anterior-posterior diameter of the chest. The abdomen is flat. The genitalia are those of an adult male. The penis appears uncircumcised. The extremities show no edema, joint deformity, abnormal mobility or needle tracks.

EVIDENCE OF THERAPEUTIC INTERVENTION:

An endotracheal tube is appropriately positioned. There are fractures of the lateral portions of both 4th ribs. There is evidence of old surgery. Scars are present on the right parietal scalp, left chest, left subumbilical portion of the abdomen, and right ankle. There has not been postmortem intervention for organ procurement.

CLOTHING:

The body was not clothed, and I did not see the clothing.

INITIAL INCISION:

The body cavities are entered through the standard coronal incision and the standard Y-shaped incision. No foreign material is present in the mouth, upper airway or trachea.

12**AUTOPSY REPORT**

No.

2012-00769

CORNELIUS, DONALD

4

Page _____

NECK:

The neck organs are removed en bloc with the tongue. No lesions are present, nor is trauma of the gingiva, lips or oral mucosa demonstrated. There is no edema of the larynx. Both hyoid bone and larynx are intact and without fractures. No hemorrhage is present in the adjacent throat organs, investing fascia, strap muscles, thyroid or visceral fascia. There are no prevertebral fascial hemorrhages. The tongue shows no trauma.

CHEST/ABDOMINAL CAVITY:

The pleural cavities contain a small quantity of straw-colored fluid. There are a few fibrous adhesions on the left. No tension pneumothorax is demonstrated. The parietal pleurae are intact. The lungs are well-expanded. Soft tissues of the thoracic and abdominal walls are well-preserved. The organs of the abdominal cavity have a normal arrangement, and none is absent. There is no fluid collection in the abdomen. The peritoneal cavity is without evidence of peritonitis. There are a few lower abdominal adhesions.

SYSTEMIC AND ORGAN REVIEW

The following observations are limited to findings other than injuries.

MUSCULOSKELETAL SYSTEM:

No abnormalities of the bony framework or muscles are present.

CARDIOVASCULAR SYSTEM:

The aorta is inelastic and of even caliber throughout, with vessels distributed normally from it. It shows moderate atherosclerosis. There is tortuosity and widening of the thoracic segment. The abdominal aorta has focal atherosclerosis without calcification. There is no dilation of the lower abdominal segment. No aneurysm is present. The major branches of the aorta show no abnormality.

12**AUTOPSY REPORT**

No.

2012-00769

CORNELIUS, DONALD

Page 5

Within the pericardial sac, there is a minimal amount of serous fluid. The heart weighs 380 grams. It has a normal configuration. The chambers are normally developed and are without mural thrombosis. The valves are thin, leafy and competent. There is no endocardial discoloration. There are no focal lesions of the myocardium. There is no abnormality of the apices of the papillary musculature. There are no defects of the septum. The great vessels enter and leave in a normal fashion. The ductus arteriosus is obliterated. The coronary ostia are widely patent. The right coronary artery is the dominant vessel. There is segmental coronary atherosclerosis resulting in up to 25% occlusion of the left anterior descending artery. No focal endocardial, valvular or myocardial lesions are seen. The blood within the heart and large blood vessels is liquid.

Within the inferior vena cava are two Greenfield filters, both of which are densely adherent to the venous wall. A portion of the distal filter has gone through the inferior vena cava and perforated the aorta, resulting in thrombus at the area of perforation and dark brown discoloration of the surrounding retroperitoneum.

RESPIRATORY SYSTEM:

Scant blood is present in the upper and lower respiratory tract. The mucosa is intact. The lungs are subcrepitant, and there is dependent congestion. The left lung weighs 430 grams, and the right lung weighs 470 grams. Small bullae are present at the superior margins of both lower lobes. The visceral pleurae are intact. The parenchyma is mildly edematous. The pulmonary vasculature is without thromboembolism.

GASTROINTESTINAL SYSTEM:

The esophagus is intact throughout. The stomach is not distended. It contains 30 grams of dark fluid. The mucosa is intact without hemorrhage or ulceration. Portions of tablets and capsules cannot be discerned in the stomach. The external appearance of the small intestine and colon is unremarkable. The small intestine and colon are examined by incision along the mesenteric border, and no mucosal lesions are present. The appendix is present. The pancreas occupies a normal position. There is early autolysis. The parenchyma is lobular and firm. The pancreatic ducts are not ectatic, and there is no parenchymal calcification.

12**AUTOPSY REPORT**

No.

2012-00769

CORNELIUS, DONALD

6

Page _____

HEPATOBIILIARY SYSTEM:

The liver weighs 1470 grams. It is red-brown, and the capsule is thin. The consistency is soft, and the cut surface is smooth. There is a normal lobular arrangement. The gallbladder is present, and its wall is thin and pliable. It contains a few cc's of bile and no stones. There is no obstruction or dilation of the extrahepatic ducts. The periportal lymph nodes are not enlarged.

URINARY SYSTEM:

The left kidney weighs 100 grams, and the right kidney weighs 110 grams. The kidneys are normally situated, and the capsules strip easily revealing a surface with several 2 to 3 cm thin-walled cysts that are filled with serous fluid. The cortico-medullary demarcation is preserved. The pyramids are not remarkable. The peripelvic fat is not increased. The ureters are without dilation or obstruction and pursue their normal course. The urinary bladder is trabeculated. It contains 30 grams of clear yellow urine.

GENITAL SYSTEM:

The prostate is mildly enlarged and nodular. Both testes are in the scrotum and are unremarkable. Large bilateral hydroceles are present.

HEMOLYMPHATIC SYSTEM:

The spleen weighs 30 grams. It is small, and the capsule is intact. The parenchyma is dark red and firm. There is no increase in the follicular pattern. Lymph nodes throughout the body are small and inconspicuous. The bone is not remarkable. The bone marrow of the ribs is red and moist.

ENDOCRINE SYSTEM:

The thyroid gland is unremarkable. The parathyroid glands are not identified. The adrenals are intact without necrosis or hemorrhage. The thymus is not identified. The pituitary gland is of normal size.

12**AUTOPSY REPORT**

No.

2012-00769

CORNELIUS, DONALD

Page 7**HEAD AND CENTRAL NERVOUS SYSTEM:**

There is subcutaneous and subgaleal hemorrhage related to the gunshot wound. The hemorrhage does not extend into the orbits but does extend into the right temporal muscle. The external periosteum and dura mater are stripped showing extensive fractures of the calvarium. There is minimal subarachnoid hemorrhage.

The brain weighs 1050 grams. The leptomeninges are thin and transparent. A normal convoluted pattern is observed. Sectioning shows extensive white matter hemorrhages, more prominent in the rostral portion of the brain, as well as a small contusion of the inferior surface of the right frontal lobe. There is extensive laceration along the gunshot wound. The ventricular system shows no dilation or distortion. The pons, medulla and cerebellum are unremarkable. There is no evidence of uncal or cerebellar herniation. Vessels at the base of the brain have a normal pattern of distribution. There is a 3 mm unruptured aneurysm of the anterior communicating artery. The cranial nerves are intact, symmetrical, and normal in size, location and course. The cerebral arteries show mild atherosclerosis.

SPINAL CORD:

The spinal cord is not dissected.

HISTOLOGIC SECTIONS:

Representative sections from various organs are preserved in two small storage jars in 10% formalin.

TOXICOLOGY:

Heart blood, femoral blood, liver tissue, urine, stomach contents, vitreous humor, and spleen have been submitted to the laboratory. A comprehensive screen is requested.

12**AUTOPSY REPORT**

No.

2012-00769

CORNELIUS, DONALD

Page 8

PHOTOGRAPHY:

Photographs have been taken prior to the course of the autopsy.

SPECIAL PROCEDURES:

The shaved hair from around the entry wound is placed into an evidence envelope and kept in my possession until it is dropped into the evidence chute following the autopsy.

RADIOLOGY:

Six x-rays are obtained. They show two filters in the inferior vena cava, as well as numerous surgical clips in the right parietal area of the brain.

WITNESSES:

Detectives Diaz and Myers of the Los Angeles Police Department witnessed the autopsy.

DIAGRAMS USED:

Diagram Forms 20, 22, 28 and 29 were been used during the course of the autopsy. The diagrams are not intended to be facsimiles.

OPINION:

The gunshot wound is a rapidly fatal wound inflicted at contact range.

Christopher Rogers
CHRISTOPHER ROGERS, M.D.
CHIEF, FORENSIC MEDICINE

3-28-12
DATE

CR:am/brr:c
D-02/03/12
T-02/07/12

13

RADIOLOGY CONSULT

2012-00769
Cornelius, Donald**REQUEST:**

The decedent is a 76-year-old black man who had a suicidal gunshot wound to the head. There was a history of previous cerebral aneurysm repair. At autopsy, two filters were present in the inferior vena cava. Please examine for disease or injury.

RADIOGRAPHIC IMAGES:


Limited radiographic survey: skull (AP, lateral), chest (AP) abdomen (AP), pelvis (AP).

FINDINGS:

There is extensive complex fracture of the calvarium consistent with history of "suicidal gunshot wound to the head". Multiple intracranial surgical clips are present within the right posterior parietooccipital region, consistent with history of "previous cerebral aneurysm repair". There is irregular hypertrophy of the superior and posterior calvarium consistent with old postoperative deformity, and subsequent calvarial remodeling. Numerous small punctate granulomatous calcifications are present within the lungs, which are consistent with chronic/old granulomatous disease, and there is aneurysmal dilatation of the aortic arch. At least two inferior vena cava filters are in place within the upper and mid abdomen and surgical clips are present within the left mid abdomen. There is old compression fracture of the upper end plate of T 12. Plastic tubing overlies the right and left pelvis.

IMPRESSION:

1. There is extensive complex fracture of the calvarium consistent with history of gunshot wound to the head.
2. Postoperative surgical clips are present within the right posterior parietooccipital cranial vault. There is also deformity of the calvarium consistent with postoperative osseous remodeling.
3. Numerous chronic pulmonary granulomatous calcifications are present as well as aneurysmal dilatation of the aortic arch.
4. Two inferior vena cava filters are present within the abdomen. There is an old compression fracture of the upper end plate of T 12.



Donald C. Boger, M.D.
Radiology Consultant

2/21/12
Date

DCB/ic
hw 2/21/12

15

AUTOPSY CLASS: A B C Examination Only D

FAMILY OBJECTION TO AUTOPSY

Date: 2-3-12 Time: 1030 Dr. Rogers
(Print)

FINAL ON: 2-3-12 By: Rogers
(Print)

APPROXIMATE INTERVAL BETWEEN ONSET AND DEATH

2012-00769
ELIUS, DONALD

SEC. 1

DEATH WAS CAUSED BY: (Enter only one cause per line for A, B, C, and D)

IMMEDIATE CAUSE:

(A) Gunshot wound of head **Rapid**

DUE TO, OR AS A CONSEQUENCE OF:

(B)

DUE TO, OR AS A CONSEQUENCE OF:

(C)

DUE TO, OR AS A CONSEQUENCE OF:

(D)

OTHER CONDITIONS CONTRIBUTING BUT NOT RELATED TO THE IMMEDIATE CAUSE OF DEATH:

Age: 75 Gender: Male Female

PRIOR EXAMINATION REVIEW BY DME

BODY TAG CLOTHING
 X-RAY (No. 6 ER) FLUORO
 SPECIAL PROCESSING TAG MED. RECORDS ea
 AT SCENE PHOTOS (No. 10 ea)

CASE CIRCUMSTANCES

EMBALMED
 DECOMPOSED
 >24 HRS IN HOSPITAL
 OTHER: _____ (Reason)

TYPING SPECIMEN

TYPING SPECIMEN TAKEN BY: _____
SOURCE: _____

TOXICOLOGY SPECIMEN

COLLECTED BY: OR
 HEART BLOOD STOMACH CONTENTS
 FEMORAL BLOOD VITREOUS
TECHNIQUE: EXT
 BLOOD SPLEEN
 BLOOD KIDNEY
 BILE
 LIVER
 URINE
URINE GLUCOSE DIPSTICK RESULT: 4+ 3+ 2+ 1+ 0
TOX SPECIMEN RECONCILIATION BY: W

NATURAL SUICIDE HOMICIDE
 ACCIDENT COULD NOT BE DETERMINED

If other than natural causes, HOW DID INJURY OCCUR? with pistol

WAS OPERATION PERFORMED FOR ANY CONDITION STATED ABOVE: YES NO

TYPE OF SURGERY: _____ DATE: _____

ORGAN PROCUREMENT TECHNICIAN: Crijalva
PREGNANCY IN LAST YEAR YES NO UNK NOT APPLICABLE

WITNESS TO AUTOPSY EVIDENCE RECOVERED AT AUTOPSY
Item Description: Hair around entry
Diaz
Myers

HISTOLOGY

Regular (No. 2) Oversize (No. _____)
Histopath Cut: Autopsy Lab

TOXICOLOGY REQUESTS

FORM 3A: YES NO
 NO TOXICOLOGY REQUESTED
SCREEN C H T S D
 ALCOHOL ONLY
 CARBON MONOXIDE
 OTHER (Specify drug and tissue)
Carbamazepine
Valproic acid

REQUESTED MATERIAL ON PENDING CASES

POLICE REPORT MED HISTORY
 TOX FOR COD HISTOLOGY
 TOX FOR R/O INVESTIGATIONS
 MICROBIOLOGY EYE PATH. CONS.
 RADIOLOGY CONS.
 CONSULT ON: _____
 BRAIN SUBMITTED
 NEURO CONSULT DME TO CUT
 CRIMINALISTICS
 GSR SEXUAL ASSAULT OTHER

RESIDENT

DME

Christophe Rogers

16

2012-00769
CORNELIUS, DONALD
SUI.

SEC. 1

EXTERNAL EXAM

Sex male
Race Black
Age 75
Height 72
Weight 210
Hair Gray
Eyes Brown
Sclera
Teeth
Mouth
Tongue Normal
Nose
Chest
Breasts
Abdomen
Scar - see Form 20 22
Genital - Un circumcised
Edema
Skin Normal
Decub
HEART Wt. 380
Pericard
Hypert
Dilat Normal
Muscle
Valves
Coronar 25% LAD

RV
LV
Septum Normal

AORTA } 2 inferior vena cava
VESSELS } filters; one barb penetrating
LUNGS Wt } aorta with old hemorrhage

R 470
L 430
Adhes mild bullous
Fluid emphysema
Atelectasis scant blood
Oedema in airways
Congest
Consol
Bronchi
Nodes

PHARYNX
TRACHEA
THYROID
THYMUS
LARYNX
HYOID
ABDOMINAL WALL FAT

PERITONEUM

Fluid } Few fibrous adhesions
Adhes

LIVER Wt 1470

Caps
Lobul
Fibros Normal
G B
Calc
Bile ducts

SPLEEN Wt 130 (12) 13 12

Color
Consist Normal
Caps
Malpig

PANCREAS Normal

ADRENALS

KIDNEYS Wt

R 110
L 100
Caps multiple thin-walled cysts
Cortex
Vessels
Pelvis
Ureter

BLADDER - 30gm urine
GENITALIA mild trabeculation

Prost - nodular
Testes - Bilateral hydroceles
Uterus
Tubes
Ovar

OESOPHAGUS - Normal
STOMACH - 30gm fluid

Contents
DUOB & SM INT
APPENDIX
LARGE INT
ABDOM NODES
SKELETON

Spine Bilateral
Marrow 4th rib
Rib Cage fractures
Long bones
Pelvis

6. Multicystic kidneys
7. Mild bullous emphysema
8. Nodular prostatic hyperplasia
9. Bilateral hydroceles

SCALP

Sex Form 28
CALVARIUM
BRAIN Wt 1150
Dura Gunshot wound
Fluid 3mm ACD
Ventric aneurysm
Vessels
Middle ears
Other
PITUITARY - Normal

SPINAL CORD

TOXICOLOGY SPECIMENS

Blood, urine, bile, liver,
stomach contents, spleen

SECTIONS FOR HISTOPATHOLOGY

2 stock jars, including
Circle of Willis and
base + dura entry
MICROBIOLOGY

DIAGRAMS 20, 22, 28, 29

X-RAYS
6 x-rays
2 IVC filters
Surgical clips in head
OTHER PROCEDURES

GROSS IMPRESSIONS

- 1. Gunshot wound of head
- 2. Aneurysm of anterior communicating artery
- 3. History of craniotomy
- 4. Two inferior vena cava filters
AS Remote perforation of aorta
- 5. Atherosclerotic cardiovascular disease

Date

2-3-12

Time

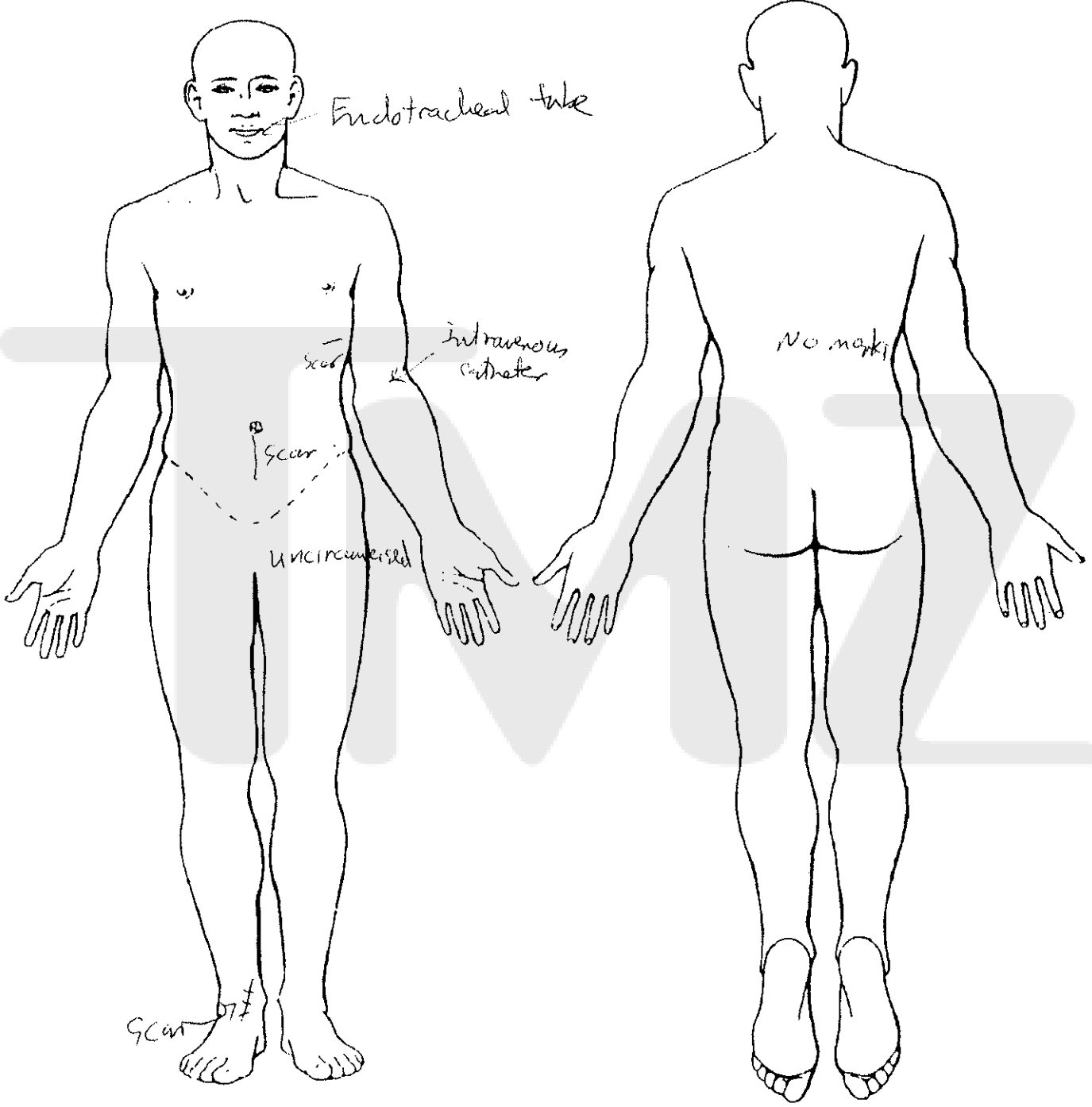
1245

Deputy Medical Examiner

Rogers

20

2012-00769
CORNELIUS, DONALD
SUI. SEC.



Date _____

Chapman 1050
2312 M.D.
Deputy Medical Examiner

22

Entry

Right temple

2 1/2 inch below top of head

2 3/4 inch right of midline

3/8 inch roughly round defect

1/2 inch laceration 4:00

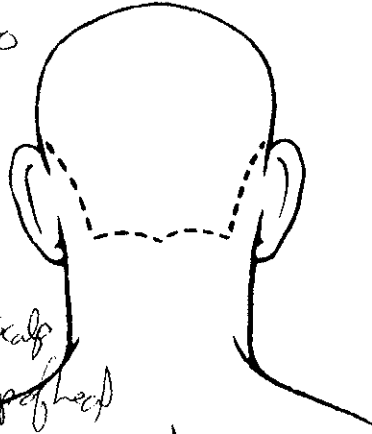
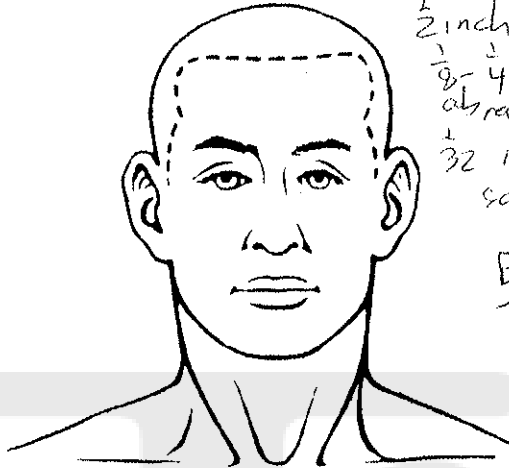
1/8 - 1/4 inch zone of abrasion

1/32 inch zone of scuff 4:00-5:00

Scuff at margin

2012-00769
CORNELIUS, DONALD
SUI.

SEC.



Exit

Left parietal scalp

1 1/2 inch below top of head

2 inch L. of midline

1 inch laceration 2:00

1 1/2 inch laceration 4:00

2 inch laceration 6:00

1 1/2 inch laceration 9:00

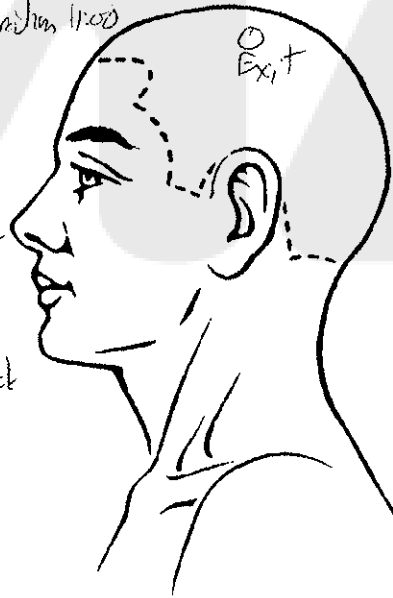
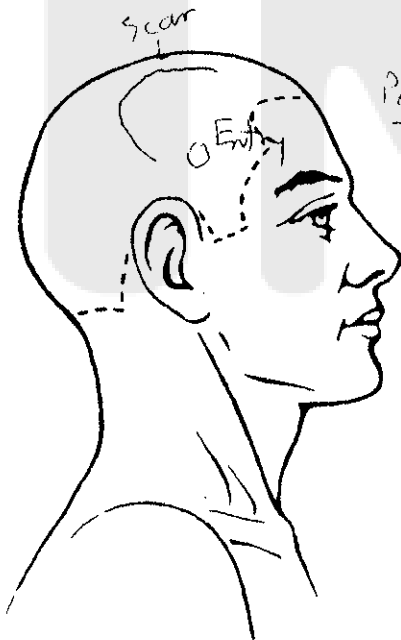1/2 inch laceration 11:00

Projectile

None

Direction

Right to left
Upward
slightly
front to back



Date

Chapman

1050
2-3-12

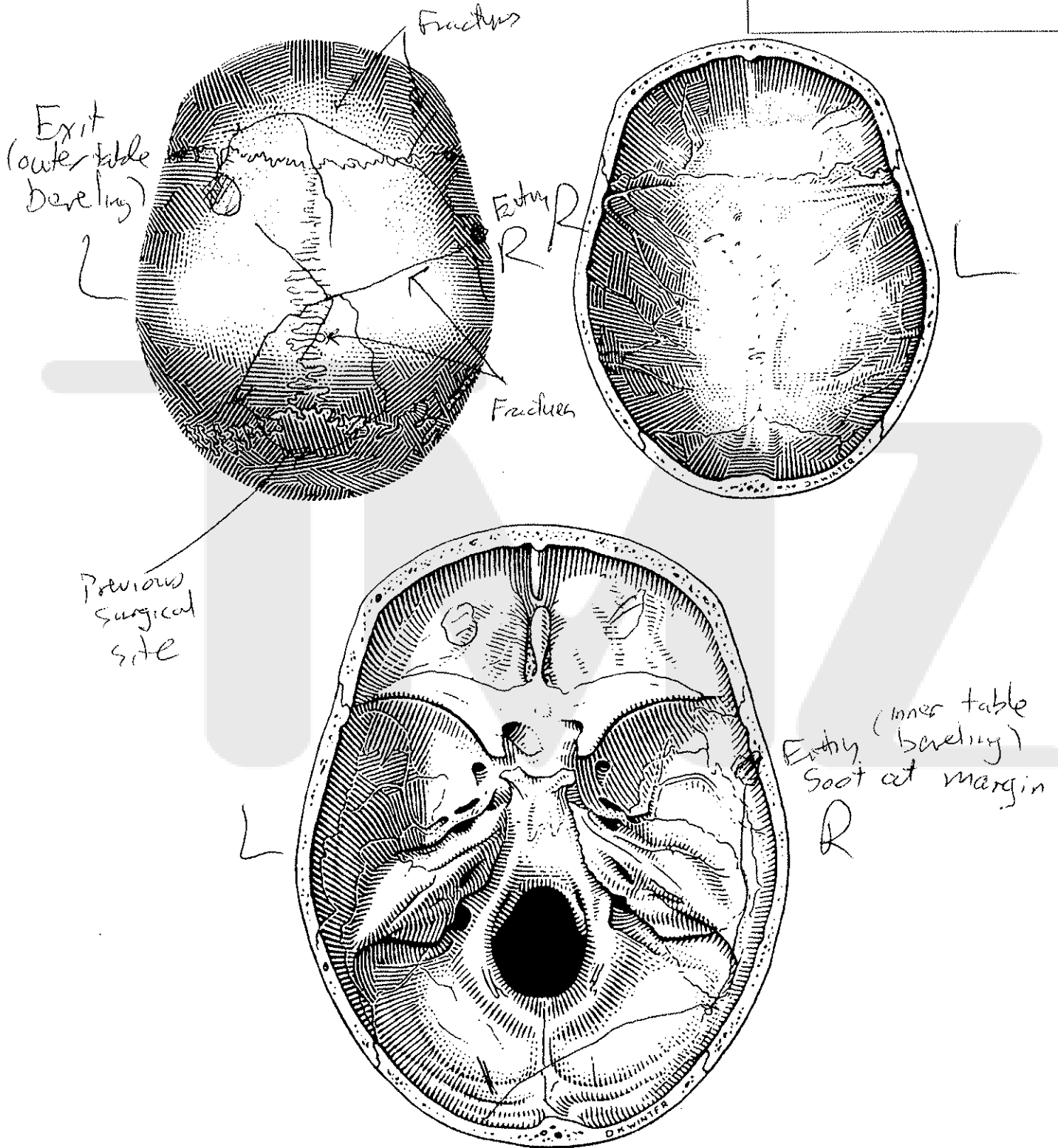
M.D.

Deputy Medical Examiner

28

2012-00769
CORNELIUS, DONALD
SUI

SEC. 1



Date

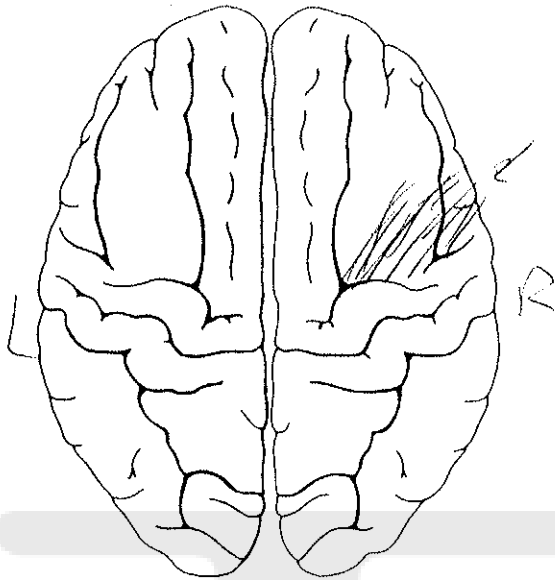
1246
2312 M.D.
Deputy Medical Examiner

29

Extensive white matter
hemorrhage, more
in front

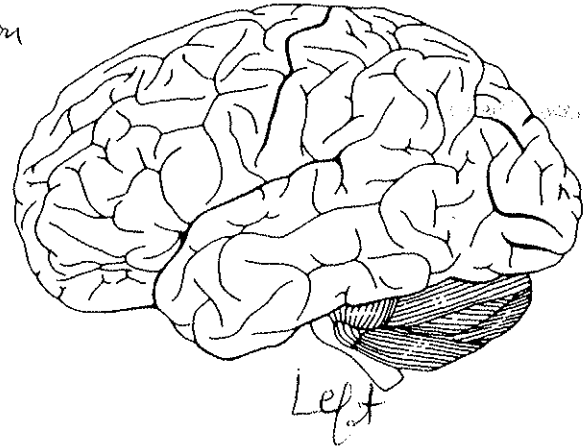
2012-00769
CORNELIUS, DONALD
SUI.

SEC.

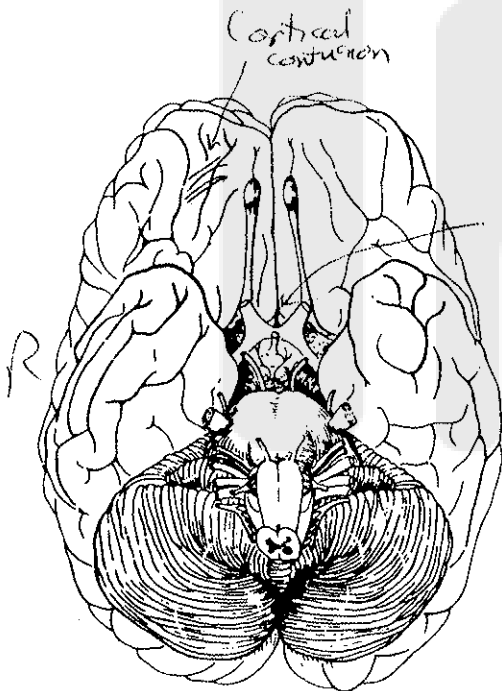


← laceration

R



Left

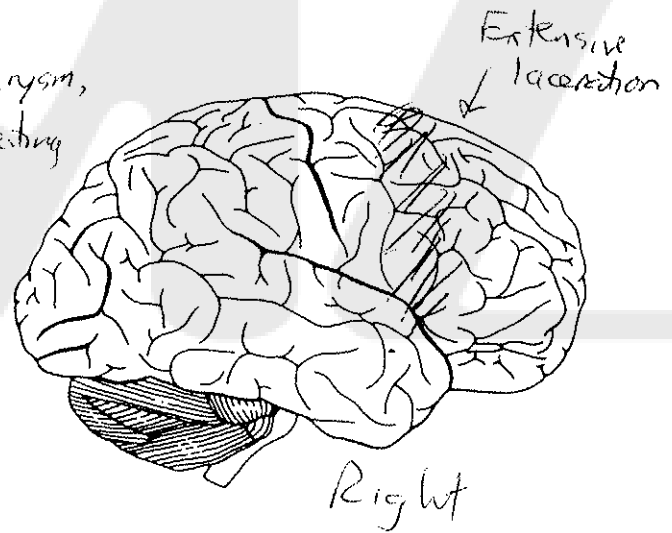


Cortical
contusion

3mm aneurysm,
anterior
communicating
artery

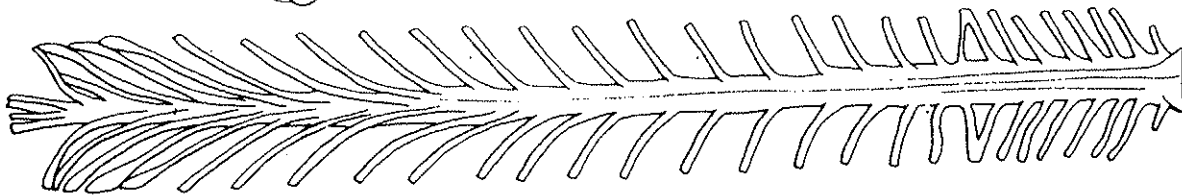
R

L



Extensive
laceration

Right



Chapman

1240
2-3-12

M.D.

Deputy Medical Examiner



Department of Coroner, County of Los Angeles
FORENSIC SCIENCE LABORATORIES
 Laboratory Analysis Summary Report



To: Dr. Rogers
 Deputy Medical Examiner

PendingTox

The following results have been technically and administratively reviewed and are the opinions and interpretations of the Analyst:

Coroner Case Number: 2012-00769 Decedent: CORNELIUS, DONALD CORTEZ

<u>SPECIMEN</u>	<u>SERVICE</u>	<u>DRUG</u>	<u>RESULT</u>	<u>ANALYST</u>
Blood, Femoral				
	Cocaine	Benzoylcegonine	ND	S. Brooks
	Cocaine	Cocaethylene	ND	S. Brooks
	Cocaine	Cocaine	ND	S. Brooks
	Neutrals	Carbamazepine	QNS	O. Pleitez
	Neutrals	Valproic Acid	QNS	O. Pleitez
Blood, Heart				
	Alcohol	Ethanol	Negative	M. Schuchardt
	Bases	Basic Drugs	ND	S. DeQuintana
	Cocaine	Benzoylcegonine	QNS	S. Brooks
	Cocaine	Cocaethylene	QNS	S. Brooks
	Cocaine	Cocaine	QNS	S. Brooks
	ELISA	Barbiturates	ND	C. Miller
	ELISA	Fentanyl	ND	C. Miller
	ELISA	Methamphetamine & MDMA	ND	C. Miller
	ELISA	Opiates: Codeine & Morphine	ND	C. Miller
	ELISA	Opiates: Hydrocodone & Hydromorphone	ND	C. Miller
	ELISA	Phencyclidine	ND	C. Miller
	Neutrals	Carbamazepine	< 10 ug/mL	O. Pleitez
	Neutrals	Valproic Acid	Present	O. Pleitez
Vitreous				
	Neutrals	Valproic Acid	Present	O. Pleitez


CR 3-27-12

SPECIMEN SERVICE DRUG RESULT ANALYST

Legend:		mg/dL	Milligram per Deciliter	QNS	Quantity Not Sufficient
g	Grams	mg/L	Milligram per Liter	TNP	Test Not Performed
g%	Gram Percent	ND	Not Detected	ug	Micrograms
Inc.	Inconclusive	ng/g	Nanograms per Gram	ug/g	Micrograms per Gram
mg	Milligrams	ng/mL	Nanograms per Milliliter	ug/mL	Microgram per Milliliter

In accordance with the Department's Evidence Retention Policy, the blood specimen(s) will be retained for one-year and all other specimens for six-months from Autopsy.

Administratively reviewed by:



Daniel T. Anderson, M.S., FTS-ABFT, D-ABC
Supervising Criminalist II
TOXICOLOGY

T M Z



COUNTY OF LOS ANGELES
DEPARTMENT OF CORONER
1104 N. MISSION RD., LOS ANGELES, CALIFORNIA 90033



Forensic Science Laboratories
Analytical Report

Report Date: 2/16/2012

Case #: 2012-00769

Decedent: Cornelius, Donald

Kit #: C7273

Collected: 2/1/2012

Analysis: Gunshot Residue

Specimen: One properly sealed GSR kit.

Purpose: Determine by Scanning Electron Microscopy / Energy Dispersive Spectroscopy (SEM/EDS) analysis if any gunshot residue particles are present.

Results: SEM/EDS analysis revealed **no particles of gunshot residue on either the right hand adhesive lift sample or the left hand adhesive lift sample.**

Therefore, the findings are inconclusive for one or more of the following reasons:

- A. The subject may not have discharged a firearm.
- B. The subject may have discharged a firearm but no gunshot residue particles were deposited on the hands.
- C. The subject may have discharged a firearm, but the gunshot residue particles were removed by washing, wiping, or other activity before the specimens were collected.

Note: It is indicated on the GSR Data Sheet that the decedent may have gone to a hospital, therefore the decedent's hands may have been touched by hospital personnel prior to the collection of the GSR sample.

Analyst: Debra K. Kowal
Senior Criminalist

Accreditations:

Peace Officer Standards and Training Certified
National Association of Medical Examiners
American Society of Crime Laboratory Directors - LAB

California Medical Association-Continuing Medical Education
Accreditation Council for Graduate Medical Education

CR 2-28-12

18

TO REPORT A DEATH — PHONE (323) 343-0711 FAX (323) 222-7041
COMPLETE ALL LINES, USE INK. IF UNKNOWN OR NOT APPLICABLE, SO STATE.

CC# 2012-00769

CEDARS SINAI MEDICAL CENTER
NAME OF FACILITY

ADDRESS 6700 BEVERLY BLVD HOSPITAL PHONE # [REDACTED]

NAME OF DECEDENT DONALD CORNELIUS

HOW IDENTIFIED _____ DOB 9/27/1936 AGE 75 SEX M RACE B

DATE OF DEATH 2/1/2012 TIME 0456

PRONOUNCED BY DR SAUM MEDICAL RECORD OR PATIENT FILE # 490 002 214

ORGAN/TISSUE DONATION INFORMATION

WAS THE NEXT-OF-KIN APPROACHED REGARDING ORGAN/TISSUE DONATION?
NO YES IF YES WHAT WAS THEIR RESPONSE? _____

DATE ADMITTED _____ TIME _____

SELF AMBULANCE (Name or R.A.#) 78

FROM _____
(STATE WHETHER HOME, HOSPITAL OR OTHER) GIVE ADDRESS (IF HOSPITAL ATTACH THEIR HISTORY)

ADMITTED BY: _____ M.D. PRIMARY ATTENDING PHYSICIAN _____

OFFICE PHONE # _____ OFFICE PHONE # _____

INJURIES _____ PLACE _____ CAUSE _____
DATE TIME (TRAFFIC, FALL, ETC.)

DESCRIBE INJURIES:

CLINICAL HISTORY:

UNKNOWN

SURGICAL PROCEDURES: STATE TYPE, DATE, TIME AND RESULTS OF ANY OPERATION OR AMPUTATION PERFORMED

WAS A BULLET OR OTHER FOREIGN OBJECTS RECOVERED? SPECIFY _____

LABORATORY: REPORT ON PATHOLOGY SPECIMENS TAKEN _____ DATE & TIME _____

LABORATORY PHONE NUMBER _____

MICROBIOLOGY CULTURE RESULTS: _____ NO _____ YES (ATTACH REPORT)

TOXICOLOGY SCREEN: _____ NO _____ YES (ATTACH RESULTS)

RADIOLOGICAL STUDIES: _____ NO _____ YES (ATTACH RESULTS)

REMARKS: ESPECIALLY SYMPTOMS PRECEDING AND DURING TERMINAL EPISODE

IN MY OPINION, THE CAUSE OF DEATH IS: _____

BY _____ M.D. -OR- _____ NURSE/HOSPITAL ADMINISTRATOR

OFFICE PHONE # _____ OFFICE PHONE # _____